CASE REPORT – OPEN ACCESS

International Journal of Surgery Case Reports 42 (2018) 175–178

Contents lists available at ScienceDirect

International Journal of Surgery Case Reports

journal homepage: www.casereports.com

A case report of cervical neurofibrosarcoma: Clinical presentation, treatment and outcome

Asmaou Dalil[a,*], Valentin Fokouo Fogha[b], Jean Evehe Vokwely[b], Emery Sougou[c], Jérôme Miloundja[c]

[a] Hôpital d'instruction des armées Omar Bongo Ondimba/General Hospital of Yaoundé, Gabon
[b] Centre Hospitalier d'ESSOS, Yaoundé
[c] Hôpital d'instruction des armées Omar Bongo Ondimba, Gabon

ARTICLE INFO

Article history:
Received 5 March 2017
Received in revised form 20 May 2017
Accepted 20 May 2017
Available online 12 December 2017

Keywords:
Neurofibrosarcoma
Neurofibromatosis
Case report

ABSTRACT

INTRODUCTION: Malignant peripheral nerve sheath tumors (MPNST) are highly aggressive soft tissue sarcomas in which complete surgical resection is the mainstay of therapy.
CLINICAL PRESENTATION: We report a case of MPNST, a 24 year old patient with right neck painful mass of 13 cm of greater dimension, skin spots, lentigos, cutaneous neurofibromas. The neck CT scan revealed a mass with liquid and soft tissues densities. Surgery was performed through right cervical Paul André incision and allowed exeresis of a hemorrhagic mass expensing on the cranial nerves X, XI, XII and the cervical sympathetic chain. Pathology analysis revealed a neurofibrosarcoma, the patient received six doses of chemotherapy. A second surgery was performed one year later after the appearance of a rapidly growing neck mass on the same site. The patient deceased in the intensive care unit one day post-op.
DISCUSSION: Neurofibrosarcoma is a rare clinical entity most often reported as case report. This tumor takes its origin from nerve structures such as the brachial plexus, the cervical sympathetic chain and the cranial nerves and their branches. The appearance of pain, size modification or signs of nerve root compression should warn us to search for a malignant degeneration. Surgery is the base of treatment, associated to radiotherapy and chemotherapy. Vinblastin and doxorubicin were used by other authors in association to radiotherapy with complete local control of inoperable tumors. The 5-year survival is 50% in patients with a neurofibrosarcoma de novo.
CONCLUSION: The prognosis of neurofibrosarcoma is poor, prompting aggressive local (surgery) and systemic treatment (radiotherapy and/or chemotherapy).
© 2017 The Author(s). Published by Elsevier Ltd on behalf of IJS Publishing Group Ltd. This is an open access article under the CC BY-NC-ND license (http://creativecommons.org/licenses/by-nc-nd/4.0/).

1. Introduction

Case reports have been a long held tradition within the surgical literature; this work has been reported in line with the SCARE criteria [1]. Neurofibrosarcoma or Malignant Peripheral Nerve Sheath Tumor (MPNST) is a rare malignant tumor arising from the sheath of peripheral nerves. Its neck location is unusual, less than 1% of the tumors of this region [2]. Neurofibrosarcomas represent about 10% of neck soft tissue sarcomas, and about half of the lesions associated to type I neurofibromatosis (NF1) or Von Recklinghausen's disease, the most prevalent phacomatosis [3]. The degeneration of a benign tumor into malignancy one usually occurs in association with a large and diffuse neurofibroma in patients suffering from NF1. The tumors presents as rapidly growing masses often associated with pain. We report the case of a 24-year-old with a right cervical neurofibrosarcoma (Table 1).

Table 1
Location of tumour, treatment and outcomes.

Tumour	Treatments	Outcomes
Right Cervical tumour (13 cm) at the expenses of the cranial nerve X, spreading extensions along cranial nerves X, XI, XII and the cervical sympathetic chain.	First surgery + chemotherapy (doxorubicin)	No event before one year of treatment. Relapse one year later
	Second surgery 1 year later	Death one day post-operative of the second surgery

2. Case report

A 24-year-old patient presented 8 months prior to the consultation a painful right lateral neck mass with dysphagia. Physical

* Corresponding author.
E-mail addresses: dalilasma@gmail.com (A. Dalil), foghaval@yahoo.fr (V. Fokouo Fogha), vokwely@yahoo.fr (J. Evehe Vokwely), sougouemery_2001@yahoo.fr (E. Sougou), jemiloundja@yahoo.fr (J. Miloundja).

https://doi.org/10.1016/j.ijscr.2017.12.019
2210-2612/© 2017 The Author(s). Published by Elsevier Ltd on behalf of IJS Publishing Group Ltd. This is an open access article under the CC BY-NC-ND license (http://creativecommons.org/licenses/by-nc-nd/4.0/).

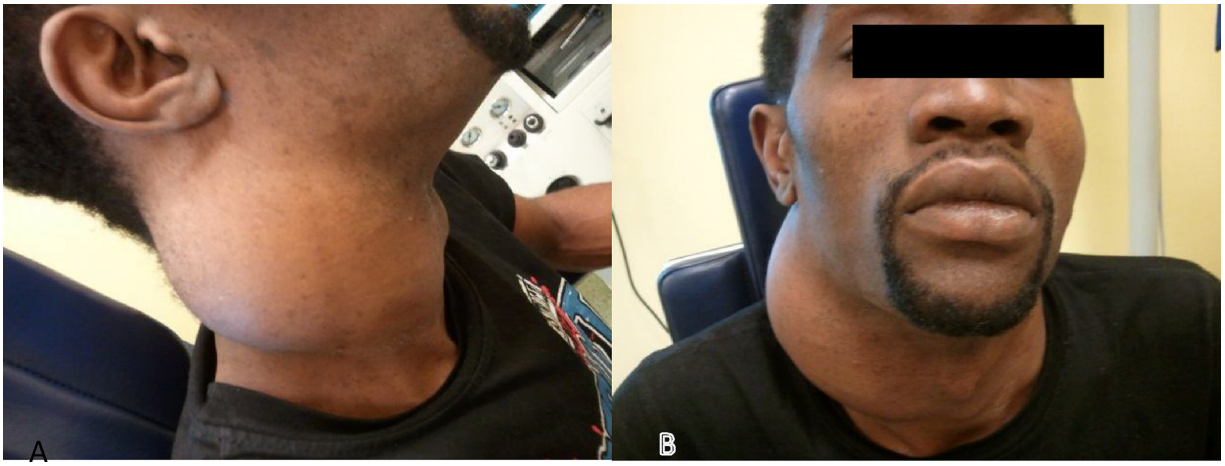

Fig. 1. View of the neck mass. A: Right lateral view. B: Front view.

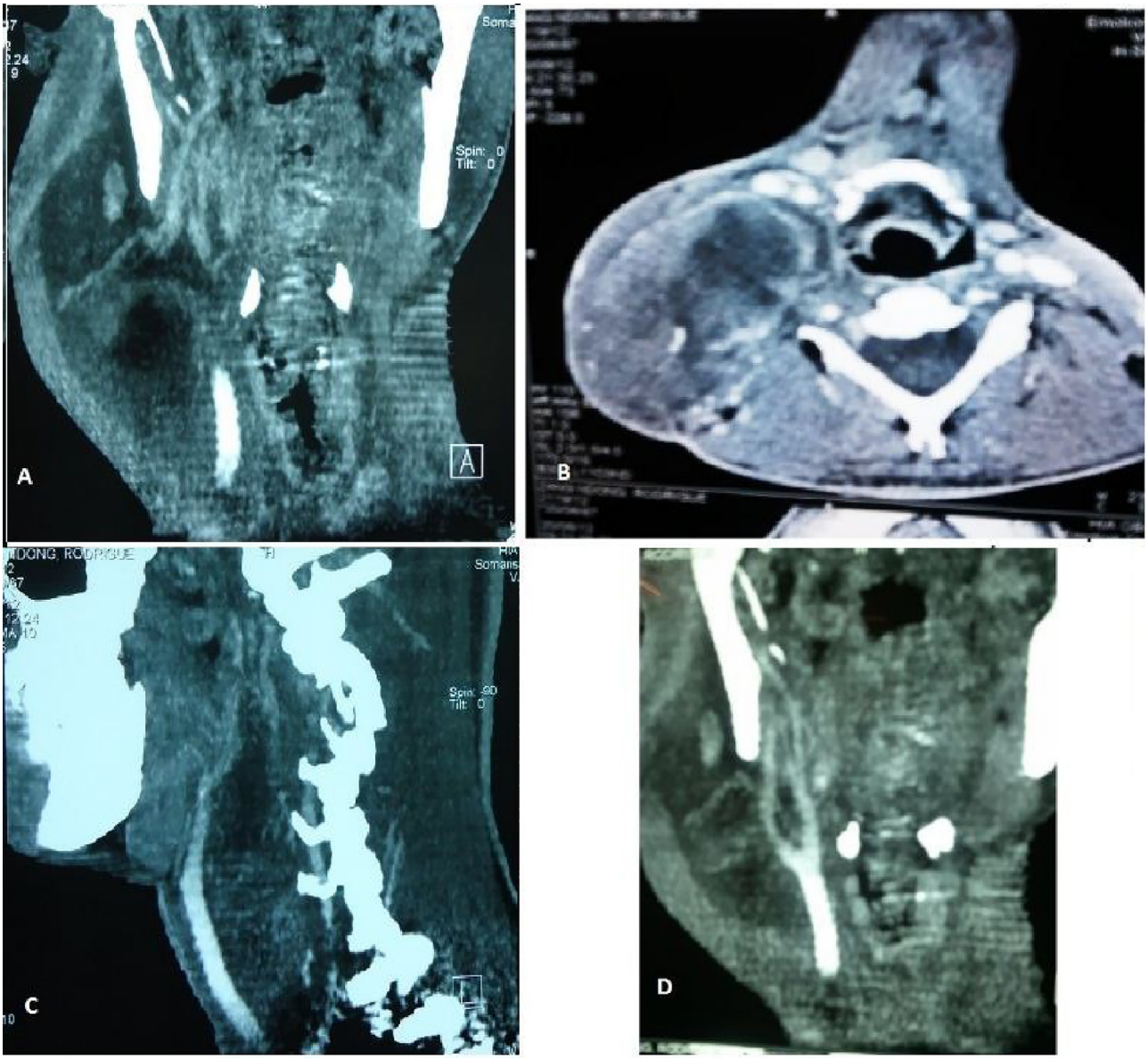

Fig. 2. CT Scan imaging of the patient.
A – Coronal view showing spots of intra tumoral necrosis
B – Axial view showing the mass effect on the right vascular axis
C – Sagittal view with contrast injection showing the relation of the mass to the carotid artery
D – Coronal view with contrast injection showing the vascular connections of the tumour.

Download English Version:

https://daneshyari.com/en/article/8832950

Download Persian Version:

https://daneshyari.com/article/8832950

Daneshyari.com