



Contents lists available at ScienceDirect

## International Journal of Surgery Case Reports

journal homepage: [www.casereports.com](http://www.casereports.com)

# A case of traumatic cardiopulmonary arrest with good neurological outcome predicted by amplitude-integrated electroencephalogram



Ko Harada\*, Kohei Tsukahara, Tetsuya Yumoto, Yasuaki Yamakawa, Atsuyoshi Iida, Hiromichi Naito, Atsunori Nakao

Department of Emergency and Critical Care Medicine, Okayama University Graduate School of Medicine Dentistry and Pharmaceutical Sciences, 2-5-1 Shikata-cho, Kitaku, Okayama 700-8558, Japan

## ARTICLE INFO

## Article history:

Received 22 January 2017

Received in revised form 22 April 2017

Accepted 30 April 2017

## Keywords:

Traumatic cardiopulmonary arrest

Amplitude-integrated

electroencephalogram

Hypoxic ischemic encephalopathy

## ABSTRACT

**INTRODUCTION:** Traumatic cardiopulmonary arrest has a very high mortality, and survival of patients with this condition without neurological disability is rare.

**PRESENTATION OF CASE:** We herein report a case of traumatic cardiopulmonary arrest secondary to accidental amputation of the left lower leg that was successfully treated without any higher brain dysfunction. Although the long duration of cardiopulmonary arrest in this patient suggested hypoxic ischemic encephalopathy, amplitude-integrated electroencephalogram showed normal findings.

**DISCUSSION:** This system may help intensivists evaluate the neurological conditions of patients with suspected hypoxic ischemic encephalopathy in the early stage of the clinical course and may assist in guiding therapeutic interventions.

**CONCLUSION:** Our case supports the usefulness of neurological monitoring using amplitude-integrated electroencephalogram.

© 2017 The Authors. Published by Elsevier Ltd on behalf of IJS Publishing Group Ltd. This is an open access article under the CC BY-NC-ND license (<http://creativecommons.org/licenses/by-nc-nd/4.0/>).

## 1. Introduction

Cardiopulmonary arrest (CPA) secondary to traumatic injury has a very high mortality, with a 2.2% overall survival rate [1]. Among those survivors, neurological disability is common, being absent in only 0.8% of those suffering from traumatic CPA [1]. However, predicting outcomes after hypoxic ischemic events including CPA still remains challenging for intensivists and emergency physicians [2,3]. We herein report a case of an out-of-hospital traumatic CPA due to hypovolemia that was successfully treated without any higher brain dysfunction in which neurological outcome could be evaluated using amplitude-integrated electroencephalography (aEEG). aEEG is a bedside neurophysiology tool that uses a limited number of channels to record raw EEG signal. Due to its ease of application and interpretation, aEEG has been widely used in these decades in the intensive care medicine. Sharing our experience may emphasize the importance of aEEG in the treatment of traumatic/hemorrhagic CPA. Our report has been reported in line with the SCARE criteria [4].

## 2. Presentation of case

A 65-year-old man was accidentally injured while driving his cultivator. His left lower leg was completely cut off by the cultivator blades. When the emergency service arrived, his heart rate was 130 beats per minute with weak pulse on the radial artery. During transport, the patient deteriorated and was noted to have cardiopulmonary arrest three minutes before arriving at the emergency room, and cardiopulmonary resuscitation was performed in the ambulance. He arrived at the emergency room 42 min after the initial notification.

On arrival, the patient was unresponsive with absent respiratory movement. Carotid and femoral pulses are not palpable and electrocardiogram showed pulseless electrical activity. Intraosseous access in right lower leg immediately and two intravenous lines in both arms were placed and tracheal intubation was performed. Massive fluid resuscitation and blood transfusion was initiated, and adrenaline 1 mg was administered three times every four minutes. Since active bleeding from the left popliteal artery was noted in spite of pneumatic tourniquet for hemostasis, his left popliteal artery was immediately clamped by forceps (Fig. 1A, B). Return of spontaneous circulation (ROSC) was achieved in 21 min. Heart rate was 110 beats per minute and regular and blood pressure was 70/50 mmHg. No inotropic support to maintain the circulation was administered. The patient was still unconscious with a Glasgow Coma Scale (GCS) score of 3 (E1VTM1)

\* Corresponding author.

E-mail address: [me422084@s.okayama-u.ac.jp](mailto:me422084@s.okayama-u.ac.jp) (K. Harada).

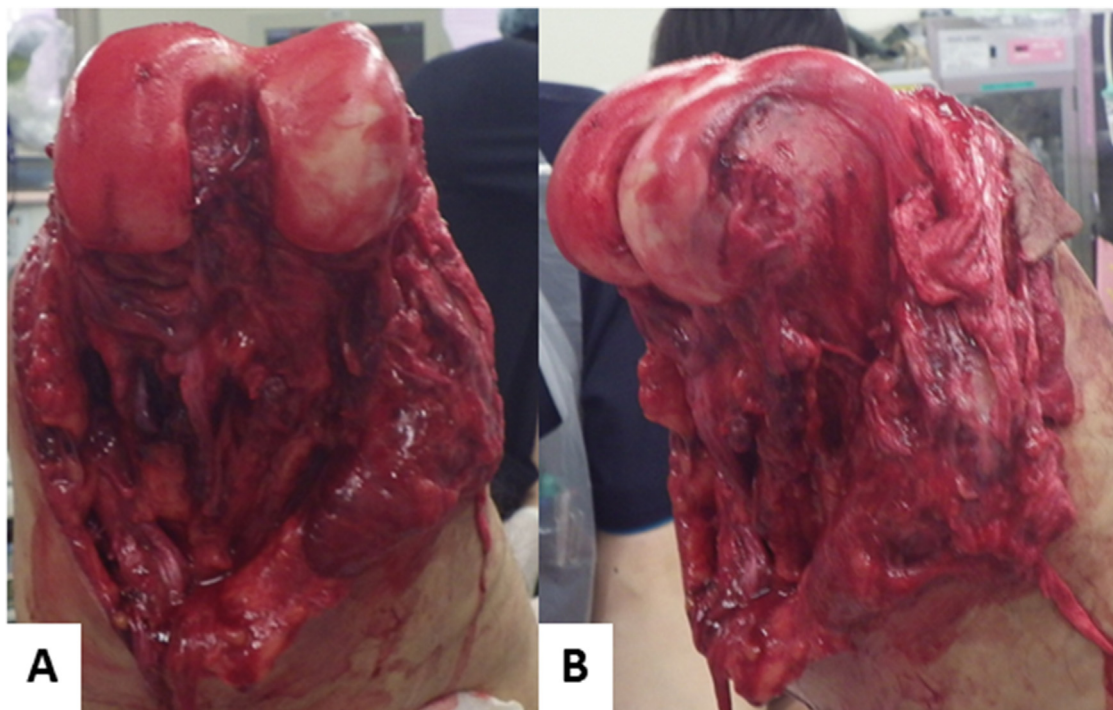


Fig 1. The patient's left lower leg was amputated at the knee joint and there was bleeding from the left popliteal artery in response to chest compression.

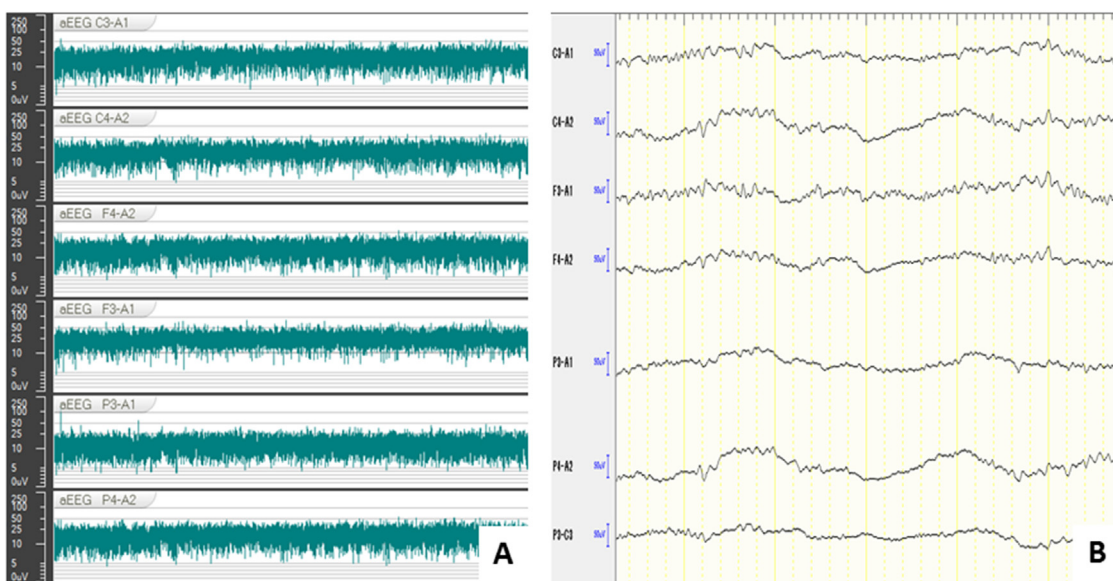


Fig. 2. Eight hours after arrival, amplitude-integrated electroencephalogram was obtained and demonstrated a continuous normal voltage (CNV) pattern. CNV aEEG levels were  $>5 \mu V$  (aEEG minimum) and  $>10 \mu V$  (aEEG maximum) (Fig. 2a). Original EEG showed 6–10 Hz wave and no abnormal wave (Fig. 2b).

without any sedative medication. Both the left and right pupils were 7.0 mm and did not respond to light. We administered antibiotics, tetanus immunoglobulin and tetanus toxoid. Computed tomography revealed no brain oedema or no other injury. Laboratory findings at presentation revealed the following values: white blood cells  $8450/\mu L$ , hemoglobin 7.2 g/dL, platelets  $6.4 \times 10^4/\mu L$ , aspartate aminotransferase (AST) 1250 U/L, creatine kinase (CK) 780 U/L, myoglobin 16,900 ng/mL, and creatinine 1.06 mg/dL. Arterial blood gas tests showed pH 7.020,  $pCO_2$  21.4 mmHg, bicarbonate 5.3 mmol/L, and lactate 18 mmol/L. The patient was then transferred to the emergency intensive care unit. Eight hours after

arrival, aEEG demonstrated a normal pattern of continuous normal voltage (CNV) associated with normal light reflex (Fig. 2).

His clinical course and laboratory findings are shown in Fig. 3. On day 2, amputation stump plasty was performed on his left leg. On day 3, his serum AST and CK levels were noted to be markedly increased to 11,031 U/L and 5137 U/L, respectively, suggesting rhabdomyolysis. Since his serum creatinine level has risen to 4.85 mg/dL due to acute kidney injury, continuous hemodiafiltration (CHDF) was administered from day 5 to day 10. He recovered consciousness with a GCS score of 11 (E4VTM6) on day 5. On day 10, the patient was extubated. The patient was transferred to another hospital on day 25 for further rehabilitation. At six months after

Download English Version:

<https://daneshyari.com/en/article/8833170>

Download Persian Version:

<https://daneshyari.com/article/8833170>

[Daneshyari.com](https://daneshyari.com)