



A rare case of subacute appendicitis, actinomycosis as the final pathology reports: A case report and literature review

G.A. Gómez-Torres^{a,*}, O.S. Ortega-García^a, E.G. Gutierrez-López^a,
C.A. Carballido-Murguía^b, J.A. Flores-Rios^a, C.R. López-Lizarraga^c, C.A. Bautista López^a,
C.F. Ploneda-Valencia^{a,**}

^a Department of General Surgery, Hospital Civil de Guadalajara “Dr. Juan I. Menchaca”, México

^b Department of Pathology, Hospital Civil de Guadalajara “Dr. Juan I. Menchaca”, México

^c Division of Surgery, Hospital Civil de Guadalajara “Dr. Juan I. Menchaca”, México

ARTICLE INFO

Article history:

Received 26 February 2017

Received in revised form 26 April 2017

Accepted 30 April 2017

Available online 15 May 2017

Keywords:

Actinomycosis

Appendicular actinomycosis

Abdominal actinomycosis

Subacute appendicitis

ABSTRACT

INTRODUCTION: Acute appendicitis is the most common indication for an emergency abdominal surgery in the world, with a lifetime incidence of around 10%. Actinomycetes are the etiology of appendicitis in only 0.02%–0.06%, having as the final pathology report a chronic inflammatory response; less than 10% of the cases are diagnosed before surgery. Here, we present the case of a subacute appendicitis secondary to actinomycosis.

CASE REPORT: A 39-year-old male presented with a twelve-day evolution of intermittent abdominal pain in the right lower quadrant, treated at the beginning with ciprofloxacin and urinary analgesic. The day of the admission he referred intense abdominal pain with nausea. An open appendectomy was preformed, finding a tumor-like edematous appendix with a diameter of approximately 2.5 cm.

DISCUSSION: Actinomyces are part of the typical flora of the oral cavity, gastrointestinal tract and vagina. The predominant form of human disease is *A. israelii*, it requires an injury to the normal mucosa to penetrate and cause disease. Abdominal actinomycosis involves the appendix and caecum in 66% of the presentations, of these, perforated appendicitis is the stimulus in 75% of the cases. A combination of antibiotic therapy and operative treatment resolves actinomycosis in 90% of cases.

CONCLUSION: Abdominal actinomycosis is an uncommon disease been the common presentation a perforated appendicitis, here we present a less common presentation of it with a non-perforated appendix.

© 2017 The Authors. Published by Elsevier Ltd on behalf of IJS Publishing Group Ltd. This is an open access article under the CC BY-NC-ND license (<http://creativecommons.org/licenses/by-nc-nd/4.0/>).

1. Introduction

Acute appendicitis is the most common indication for an emergency abdominal surgery in the world, with a lifetime incidence of around 10% [1,2]. The etiology of acute appendicitis is secondary to appendiceal obstruction, the commonest causes of this obstruction are lymphoid hyperplasia and, fecal stasis with fecaliths [3–5]; other rare causes have been described such as carcinoid tumor of the appendix, pinworm, eosinophilic appendicitis, granulomas, and actinomycosis among others [3,5,6].

Actinomycosis species are gram-positive bacteria, which are normal commensals of the oral cavity, gastrointestinal, and urogenital tract, but become pathogenic in the presence of necrotic tissue

[7–9]. It is reported, that actinomycetes are the etiology of appendicitis in only 0.02%–0.06% [3,5,6], having as the final pathology report a chronic inflammatory response. The usual clinical scenario is an indolent course with unspecific symptoms and signs, and less than 10% of the cases are diagnosed before surgery [8–10]. Here, we present the case of a subacute appendicitis secondary to actinomycosis. The following accomplishes the SCARE criteria [11].

2. Case presentation

A 39-year-old male presented to the emergency room with a twelve-day evolution of intermittent abdominal pain in the right lower quadrant, treated at the beginning with ciprofloxacin and urinary analgesic like a urinary tract infection.

Three days before surgery his symptoms got worse, started with fever, nausea, and vomiting. The day of the admission he referred intense abdominal pain with nausea. On physical examination the patient was in bad shape with a temperature of 38.5 °C, the abdomen was tenderness with Blumberg and McBurney signs presents, no palpable mass detected. The patient showed

* Corresponding author at: Departament de General Surgery, Hospital Civil de Guadalajara “Dr. Juan I. Menchaca”, Salvador Quevedo y Zubieta Street #750, Guadalajara, Jalisco, México.

** Corresponding author.

E-mail address: plonecef@gmail.com (G.A. Gómez-Torres).

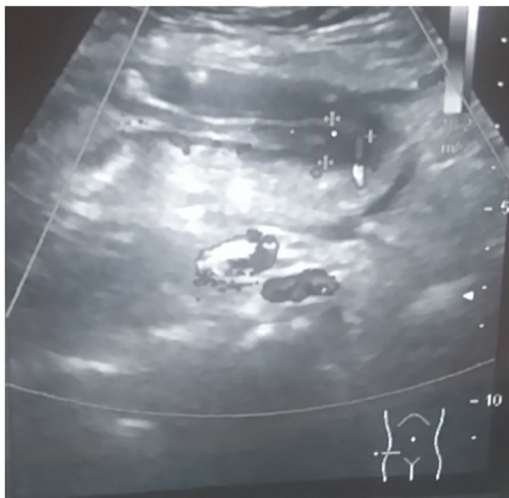


Fig. 1. Abdominal ultrasound is showing the appendix between the marks with peri-appendicular edema.

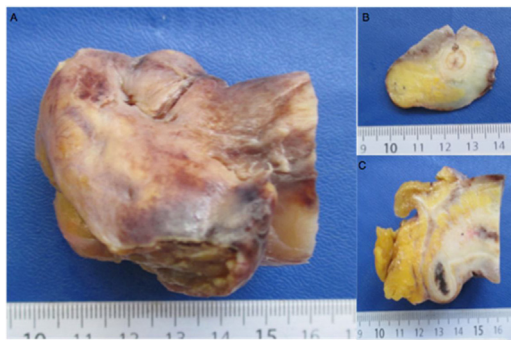


Fig. 2. (A) Tip of the appendix. (b) Fistulous path and (C) fibrous formation around the appendix.

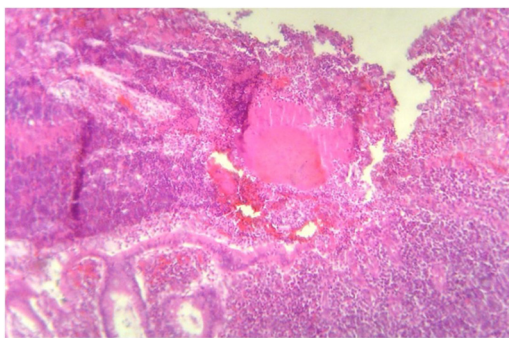


Fig. 3. Typical sulfur granule surrounded by an acute inflammatory process with ulceration of the mucosa. (HE 100 \times).

an abdominal ultrasound where free liquid in the right iliac fossa was seen, the cecal appendix measured 58 \times 10 \times 11 mm, was non-compressible, with peri-appendicular edema (see Fig. 1).

The patient was admitted to the operating room for an open appendectomy. The appendix was located in a pelvic position; it was tumor-like edematous with a diameter of approximately 2.5 cm. We did a Parker Kerr technique, without complications. The patient had a normal evolution and was discharged on the second postoperative day with oral antibiotic treatment.

The pathology report showed chronic fistulized appendicitis with transmural lymphoid infiltration (Fig. 2), the presence of sulfur granules compatible with actinomycosis (Fig. 3), and silver stain-

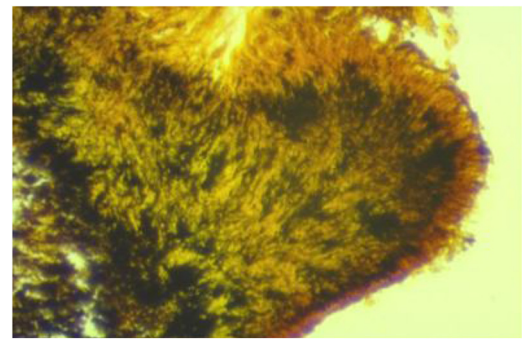


Fig. 4. Silver staining showing filamentous bacilli dyed black (Warthin-Starry 100 \times).

ing with filamentous bacilli dyed black (Fig. 4). Six months after surgery there is no complaints or recurrence of actinomycosis, he is currently under treatment.

3. Discussion

In 1886, Reginald Fitz described the physiopathology of the acute appendicitis; in 1999, Stevenson [12] introduced the term appendiceal colic and chronic appendicitis. Only 1% of patients with appendicitis had symptoms for more than a week [13]; the non-acute variants of appendicitis, includes recurrent, subacute, and chronic appendicitis, which are rarely diagnosed and remain subjects of case reports [14]. Chronic appendicitis, is a rare entity, that should be suspected in patients with more than seven days with abdominal pain in the right iliac fossa (generally at least two to three weeks) [4,14,15]; its precise etiology is unknown, recurrent appendicitis is thought to occur from transient obstruction of the appendix or secondary to excessive mucus production, while chronic appendicitis is secondary to partial but persistent obstruction of the appendiceal lumen [15].

Limaïem et al. [6], reported in a retrospective study of 1627 cases of appendectomy specimens, only one sample had actinomycosis (0.06%). Cunningham et al. [5], found that only two patients in their series of 4236 samples, had actinomycosis, that represents 0.04%. Alemayehu et al. [3], studied 3602 appendicular samples, and only one of them had actinomycosis (0.02%).

The overall incidence of actinomycosis is virtually unknown; the estimated population prevalence is one case per 40–119,000 [8]. Actinomyces are part of the typical flora of the oral cavity, gastrointestinal tract and vagina, been gram-positive bacteria, nonsporing absolute or facultative anaerobes that require an anaerobic carbon dioxide rich medium for culture [7–9,16]. The predominant form of human disease is *A. Israelii*, with occasional cases caused by *A. Naeslundii*, *Odontolyticus Viscosus* or *Meyeri* [4,7,8,16]; it requires an injury to the normal mucosa to penetrate and cause disease; such as appendicitis, diverticulitis, gastrointestinal perforations, previous surgery, foreign bodies, or neoplasia [7–10].

The peak incidence of actinomycosis is reported to occur in middle-aged individuals [9,17], although, is described that is more frequent in men with a relation M:F of 3:1 [7,8], the largest cases series that we found of abdominal actinomycosis by Choi et al. [10] reported 22 cases of abdominopelvic actinomycosis, with an M:F ratio of 1:10. They found an association with the use of an intrauterine device with the presence of the disease (60%).

Actinomycosis commonly occurs in three distinct forms that may occasionally overlap, cervicofacial presentation in 50%, abdominopelvic in 20%, and intrathoracic form in 15% [7–9]. Abdominal actinomycosis involves the appendix and caecum in 66% of the presentations [18,19], of these, perforated appendicitis is the stimulus in 75% of the cases [19]; therefore, as in our case, the

Download English Version:

<https://daneshyari.com/en/article/8833174>

Download Persian Version:

<https://daneshyari.com/article/8833174>

[Daneshyari.com](https://daneshyari.com)