




Contents lists available at ScienceDirect

International Journal of Surgery Case Reports

journal homepage: www.casereports.com

A case of obturator hernia leading to right thigh abscess in China

Zhen Shen^a, Chen-yang Zhi^b, Ruo-nan Wang^a, Hai-cheng Gao^{c,*}^a Department of Surgery, China-Japan Union Hospital of Jilin University, Changchun, 130041, China^b Department of Surgery, Changchun University of Chinese Medicine, Changchun, 130000, China^c Department of Drug, Jilin University School of Pharmaceutical Sciences, Changchun, 130021, China

ARTICLE INFO

Article history:

Received 28 July 2016

Received in revised form 15 October 2016

Accepted 15 October 2016

Available online 19 October 2016

Keywords:

Obturator hernia

Thigh abscess

Severe infection

ABSTRACT

The purpose of this case is to investigate a case of obturator hernia leading to right thigh abscess on 68-year-old woman of China. A 68-year-old Chinese woman was referred to China-Japan Friendship Hospital of Jilin University with abdominal pain, bloating, exhaust, stop defecation in 2011. She had chronic bronchitis, emphysema with a history of 20 years. This patient did not have any bad habits, such as smoking, alcohol consumption, etc. In this surgery, CT was used to diagnose the basic condition of the patient. Surgery was used for treatment of patients with diseases. In addition, this operation was performed by the china-japan Friendship Hospital of Jilin University. The results of this case showed that the cervix of rectal right anterior wall can hit a funicular neoplasm, toughening, smooth, with tenderness, considering for the external pressure bowel loops. The inside of the right thigh showed obvious swelling, skin slightly bruising, and tenderness. Chest radiographs showed that patients had emphysema, multiple planes of fluid and air in the abdomen. Patients had been successfully operated, but she died because of severe infection.

© 2016 The Authors. Published by Elsevier Ltd on behalf of IJS Publishing Group Ltd. This is an open access article under the CC BY-NC-ND license (<http://creativecommons.org/licenses/by-nc-nd/4.0/>).

1. Introduction

An obturator hernia is a rare type of hernia of the pelvic floor, pelvic or abdominal contents can go through the obturator foramen [1]. Because of differences in anatomy, it occurs mainly in women, especially in the thin elderly women [2]. According to reports obturator hernias are rare in acute surgical wards, accounting for only 0.07% of all hernias. Obturator is the channel of pelvic through thigh [3]. It located above the obturator membrane, its size can accommodate fingertips [4]. In addition, the presence of aberrant obturator vessels is a relatively common anatomic variation [5]. Patients commonly present with symptoms of intestinal obstruction [6]. However, characteristic of the perforation of gangrenous bowels are diagnosis or surgical interventions contributing directly to the high morbidity and mortality rates [7]. Obturator hernia associated with abscess is very rare disease, it may lead to severe infection and takes time to completely heal [8]. We herein reported a case of a perforated obturator hernia with a thigh abscess, but the patient died due to severe infection. The work has been reported in line with the SCARE criteria [9].

1.1. Case report

A 68-year-old Chinese woman was referred to our hospital with abdominal pain, bloating, exhaust, stop defecation in 2011. She has chronic bronchitis, emphysema with a history of 20 years. The cervix of rectal right anterior wall can hit a funicular neoplasm, toughening, smooth, with tenderness, considering for the external pressure bowel loops (Fig. 1). The inside of the right thigh showed obvious swelling, skin slightly bruising, and tenderness. Chest radiographs showed that patients had emphysema, had multiple planes of fluid and air in the abdomen (Fig. 2).

Part of the bowel loops can be seen by right hip obturator tube to the thigh triangle. It will see bigger hernial sac, cystic wall thickening. The surrounding adipose tissue can be seen a slightly higher density and diffusion of gas density (Fig. 3). We determined that obturator hernia was associated with inflammatory exudates, therefore, emergency surgery was performed (Fig. 4).

Take down the right side of the abdomen through the abdominal rectus incision about 15 cm. Abdominal can be seen light yellow thin liquid 30 ml. Intestinal segment incarcerated in the right obturator from the ileocecal part 40 cm. The collar of obturator hernia is about 25 cm. It can't be made. The right thigh cut into longitudinal incision (Fig. 5). Cutting the skin, it was darker gray, muddy, with the smell of liquid effluent, see the incarceration of the intestine. It was dark purple, like the film, complete necrosis (Fig. 6). Row

* Corresponding author.

E-mail address: gaohc19814271@126.com (H.-c. Gao).

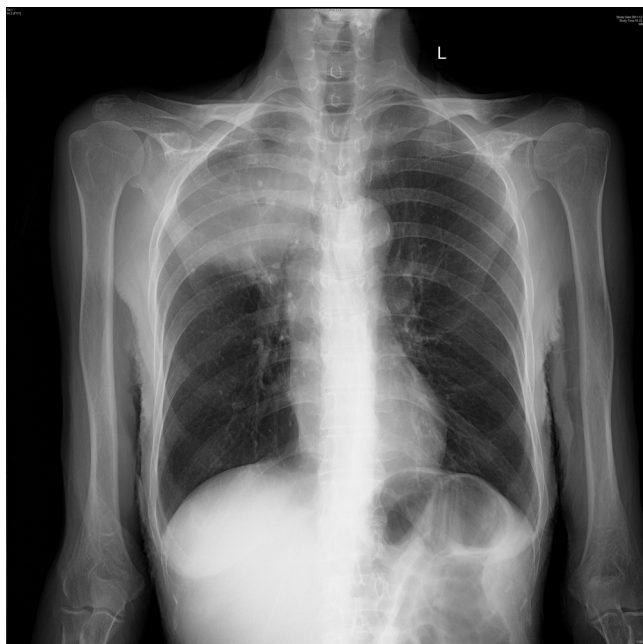


Fig. 1. Lung CT.

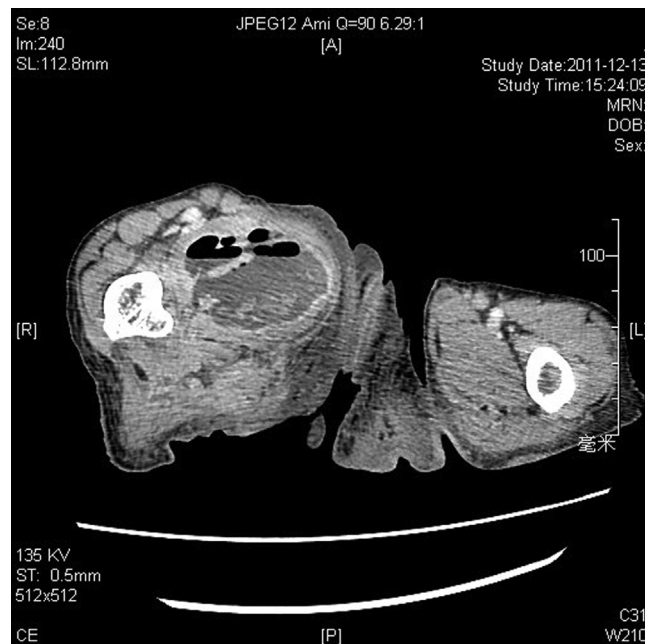

Fig. 3. MRI of thigh.

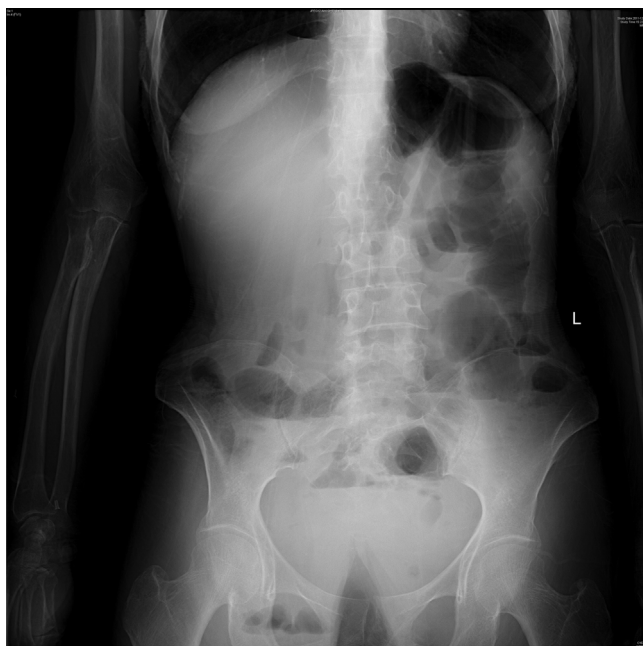


Fig. 2. Thigh CT.

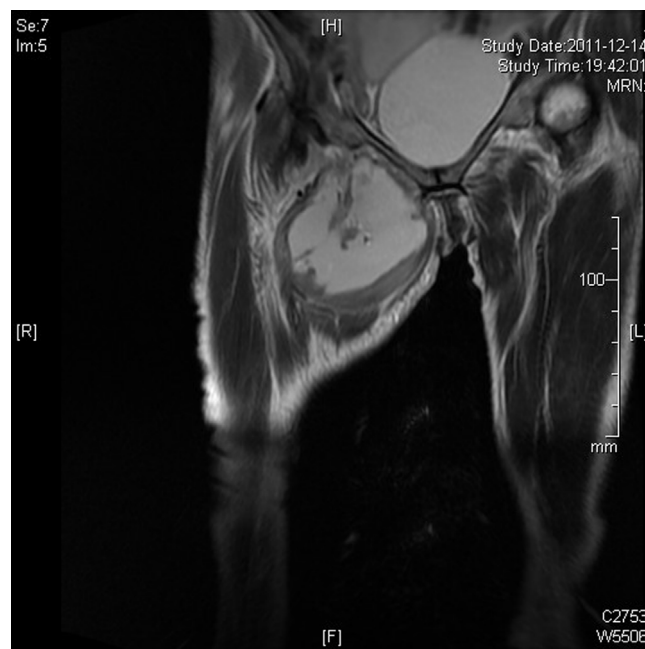


Fig. 4. MRI of thigh.

bowel was cut and flush right thigh abscess. Postoperative patients had already died with severe infection, heart and lung failure in the ICU.

2. Discussion

Pelvic obturator hernia is relatively rare type of hernia [4]. It is more common in older women with thinning, birth history of multiple pregnancy, chronic cough, habitual constipation [10]. The irruptive obturator tube of obturator hernia was incarcerated in the pipe between the pubic and obturator muscle [11]. Hernia contents included the small intestine, colon, omentum, uterus and

accessories [12]. The disease of Howship Romberg is the most characteristic signs [13]. Thus, any delay in a diagnosis may lead to necrosis and perforation of the small bowel or a concomitant thigh abscess. However, diagnostic imaging led to improvements in the diagnosis rate of obturator hernias using computed tomography (CT) and other imaging techniques in recent years [14]. But the only treatment for obturator hernias is surgery. An obturator hernia with a thigh abscess is extremely rare in china. In this case, resection of the perforated section of the small bowel and drainage of the thigh abscess are both performed in a single surgical procedure [14]. Recent advances in the use of CT and other imaging methods led to an increase in the early diagnosis of obturator hernias [14].

Download English Version:

<https://daneshyari.com/en/article/8833324>

Download Persian Version:

<https://daneshyari.com/article/8833324>

[Daneshyari.com](https://daneshyari.com)