

# Preservation of internal iliac arteries during endovascular aneurysm repair using “eye of the tiger” technique

Tariq Almerey, MD, and W. Andrew Oldenburg, MD, Jacksonville, Fla

## ABSTRACT

Parallel endografts were introduced as a way to expand endovascular repair of aneurysms involving branch vessels. However, endoleaks as a result of the gutters between the parallel endografts made this technique less favorable. The “eye of the tiger” technique was introduced to reduce the gutters between the parallel endografts proximally in the aorta. We report endovascular repair of infrarenal abdominal aortic aneurysm using eye of the tiger technique distally to preserve the internal iliac arteries. (*J Vasc Surg Cases and Innovative Techniques* 2017;3:257-60.)

Endovascular aneurysm repair (EVAR) is the most common treatment for abdominal aortic aneurysm (AAA) because of the decreased morbidity and mortality compared with conventional open repair.<sup>1,2</sup> However, complex aneurysms involving or close to branch vessels fall out of the device companies' instructions for use for EVAR. To avoid complicated open surgery, a variety of open debranching procedures have been described to expand the use of endograft repair of aortic aneurysms (ie, iliorenal, superior mesenteric artery, or celiac bypass and external iliac to internal iliac bypass). “Off-label” parallel endografts have been introduced as an “all endovascular option” for repair of complex aneurysms. This technique entails placement of one or more covered stents alongside the main aortic endograft to maintain flow through the branch vessels. This technique has not been described in managing unusual iliac anatomy. Increasing attention has been devoted to preservation of the internal iliac arteries (IIAs) because of the high incidence of buttock or hip claudication (28%) and impotence (17%) after ligation or embolization of the IIA.<sup>3</sup> Unfortunately, endoleak due to the imperfect seal of multiple stents side by side is the major weakness. The “eye of the tiger” technique was introduced to address the imperfect seal in parallel endografts. We report successful endovascular repair of infrarenal AAA with the eye of the tiger technique distally to preserve the IIAs in a patient in whom an iliac branch graft could not be used because of short nonaneurysmal common iliac

arteries. The patient's consent for publication was obtained.

## CASE REPORT

A 74-year-old man presented with infrarenal AAA measuring 5.5 cm that had increased in size from 4.4 cm 2 years ago. Computed tomography angiography demonstrated bilateral IIAs originating within 15 mm of the aortic bifurcation (Fig 1), preventing EVAR under the device's instructions for use. His past medical history was significant for hypertension, hyperlipidemia, tobacco abuse, congestive heart failure, ascending aortic aneurysm, and renal cell and prostate cancer. He previously had undergone ascending aorta replacement, coronary artery bypass grafting, left radical nephrectomy, prostatectomy, and trans-aortic valve repair for severe aortic insufficiency. Because of the patient's cardiac condition and his preference, we recommended an all endovascular repair. To avoid potential complications of buttock or hip claudication, impotence, and colon ischemia, the eye of the tiger technique was used distally to preserve the IIAs.

During surgery, an aortogram was obtained through right groin access to confirm the distance from the right renal artery to the aortic bifurcation. A 12F sheath was positioned in the distal aorta using left groin access. An 18F DrySeal Sheath (W. L. Gore & Associates, Flagstaff, Ariz) was delivered into the distal aorta over a 0.035-inch Lunderquist wire through the right common femoral artery. A Gore Excluder stent graft (28.5 × 14.5 × 160 mm) was delivered through the 18F sheath and deployed in the infrarenal aorta with the contralateral limb oriented to the patient's right. A Gore Contralateral Leg Endoprosthesis (16 × 14.5 × 120 mm) was next passed into the contralateral gate and deployed down to just above the aortic bifurcation (Fig 2, A).

A right axillary cutdown was performed in light of the patient's previously having had a left inferior mesenteric artery coronary bypass graft to decrease the risk of perioperative myocardial infarction. An 8F sheath was passed over a 0.035-inch Rosen wire through the right axillary artery access into the main body of the Gore Excluder aortic stent graft. Using a 5F vertebral catheter along with a 0.035-inch Glidewire (Terumo Medical Corporation, Somerset, NJ), the wire was advanced through the contralateral limb into the right IIA. The Glidewire was

---

From the Division of Vascular Surgery, Mayo Clinic Florida.

Author conflict of interest: none.

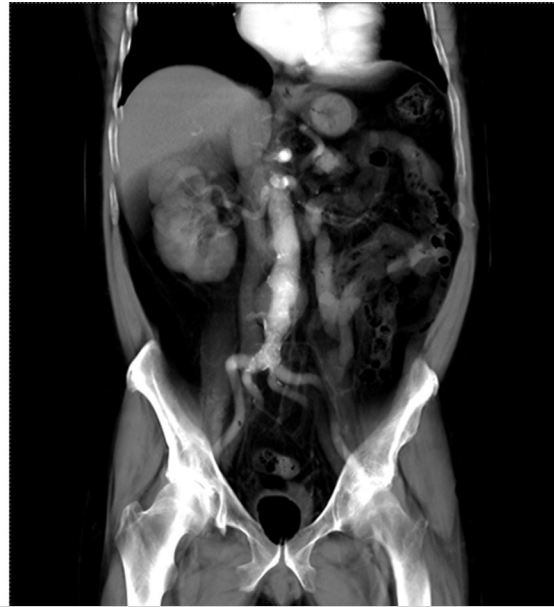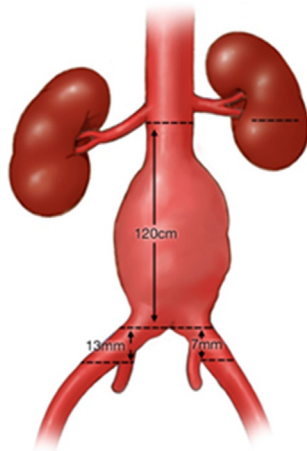
Correspondence: W. Andrew Oldenburg, MD, Division of Vascular Surgery, Mayo Clinic Florida, 4500 San Pablo Rd S, Jacksonville, FL 32224 (e-mail: [oldenburg.andrew@mayo.edu](mailto:oldenburg.andrew@mayo.edu)).

The editors and reviewers of this article have no relevant financial relationships to disclose per the Journal policy that requires reviewers to decline review of any manuscript for which they may have a conflict of interest.

2468-4287

© 2017 The Authors. Published by Elsevier Inc. on behalf of Society for Vascular Surgery. This is an open access article under the CC BY-NC-ND license (<http://creativecommons.org/licenses/by-nc-nd/4.0/>).

<https://doi.org/10.1016/j.jvscit.2017.10.007>



**Fig 1.** Three-dimensional computed tomography angiogram and illustration showing the preoperative anatomy and measurements.

exchanged for a 0.035-inch Rosen wire, and the 8F sheath was advanced into the right IIA. An 8- × 79-mm Viabahn VBX balloon-expandable endoprosthesis (W. L. Gore & Associates) was passed through the 8F sheath down into the right IIA and extending up into the contralateral limb but not deployed. Next, a 14- × 120-mm iliac extension limb was passed over the Lunderquist wire in the right groin and intussuscepted into the contralateral limb alongside the Viabahn VBX balloon-expandable endoprosthesis but not deployed. The proximal edge of the VBX stent graft was positioned so that it would deploy higher than the iliac extension limb by ~1 cm. The Viabahn VBX endoprosthesis was dilated (Fig 2, B). The 8-mm VBX balloon was exchanged for a 6- × 80-mm angioplasty balloon catheter, which was passed into the VBX graft in the right IIA but not inflated. The 14- × 120-mm right iliac extension limb stent graft was next deployed (Fig 2, C). Next, using a Coda balloon, the right external iliac limb stent graft was angioplastied to profile. At the same time, the 6-mm angioplasty balloon in the right IIA was inflated as well (Fig 2, D).

The 8F sheath that was in the contralateral limb was relocated into the ipsilateral limb of the aortic endoprosthesis, and a wire was advanced into the left IIA. In a similar fashion to the right side, an 8- × 79-mm Viabahn VBX endoprosthesis was passed through the sheath and positioned in the left IIA. Subsequently, a 14- × 120-mm Gore iliac extension stent graft was passed up the left leg and intussuscepted into the ipsilateral limb of the main body device but not deployed. The Viabahn endoprosthesis was deployed, and the balloon was removed and exchanged for a 6- × 80-mm angioplasty balloon that positioned into the Viabahn stent graft. Next, the left Gore iliac extension stent graft was unsheathed and balloon angioplastied with a Coda balloon.

While inflated, the Viabahn VBX stent graft was expanded using the 6-mm angioplasty balloon. Total fluoroscopy time was 55 minutes, and 190 mL of Visipaque contrast medium was used.

Completion aortography demonstrated widely patent renal arteries, aortic stent graft, iliac extension grafts, Viabahn VBX parallel endoprostheses, and IIAs, with no evidence of endoleak. Computed tomography angiography a month later revealed stable aneurysm size with no evidence of type I endoleak and small type II endoleak at the inferior mesenteric artery origin. The bilateral external iliac stent grafts, the parallel internal iliac Viabahn VBX endoprostheses, and both IIAs were widely patent (Fig 3). The patient's creatinine concentration was unchanged from preprocedure levels.

## DISCUSSION

Treatment of complex aneurysms involving proximal branch vessels is extremely challenging and can exclude endovascular repair as an option for repair. Parallel endografts helped in extending the applicability of EVAR in treating these complex aneurysms.<sup>4,5</sup> Although this technique provided an off-label option for complex anatomy and extended the applicability of EVAR, the imperfect seal due to the gutters between the grafts is a disadvantage with this technique. Lobato and Camacho-Lobato<sup>6</sup> introduced overlapping of at least 5 cm to induce gutter thrombosis. Minion<sup>7</sup> suggested transforming the round grafts to eye-shaped grafts by ballooning the parallel grafts (eye of the tiger technique). This technique decreases the gutters between the parallel grafts and improves the seal. The steps for eye of the tiger technique are as follows:

Download English Version:

<https://daneshyari.com/en/article/8836000>

Download Persian Version:

<https://daneshyari.com/article/8836000>

[Daneshyari.com](https://daneshyari.com)