

Association of Immune-Mediated Cerebellitis With Immune Checkpoint Inhibitor Therapy

Joanna Zurko, MD, and Amitkumar Mehta, MD

Abstract

Immune-mediated encephalitis related to immune checkpoint inhibitor therapy is a rare but increasingly described condition that can cause significant morbidity. There are several reported cases in the literature but no previously described cases of immune-mediated cerebellitis. We describe a case of acute cerebellitis that developed in a 20-year-old man with primary refractory Hodgkin lymphoma being treated with the immune checkpoint inhibitor nivolumab. After exposure to 3 cycles of nivolumab, the patient had acute onset of headache, ataxia, nausea, and vomiting, with imaging findings of cerebellar edema, early tonsillar herniation, and early hydrocephalus. Immune-mediated cerebellar encephalitis was suspected and high-dose dexamethasone therapy (8 mg every 6 hours) was initiated. Within 4 days of dexamethasone therapy, his symptoms greatly improved with near-complete resolution of symptoms after a 4-week taper. Differential diagnosis of his condition included viral cerebellitis and paraneoplastic cerebellar degeneration. In cerebellar encephalitis suspected to be due to immune checkpoint inhibitor therapy, prompt recognition and early initiation of high-dose corticosteroids is essential for symptom resolution and treatment success, including the prevention of hydrocephalus and tonsillar herniation. Currently, there are no evidence-based guidelines to guide the initial dose, type, or duration of corticosteroids. Further investigation is needed in the pathogenesis and treatment of cerebellar encephalitis related to immune checkpoint inhibitor therapy to effectively treat this rare, disabling condition.

© 2018 Mayo Foundation for Medical Education and Research. Published by Elsevier Inc. This is an open access article under the CC BY-NC-ND license (<http://creativecommons.org/licenses/by-nc-nd/4.0/>) ■ *Mayo Clin Proc Inn Qual Out* 2018;2(1):74-77



From the Division of Hematology and Oncology, Department of Medicine, University of Alabama at Birmingham, Birmingham, AL.

Since the approval of ipilimumab for the treatment of melanoma in 2011, immune checkpoint inhibitors (ICIs) have been changing the landscape of oncology. They up-regulate the body's own antitumor immunity and include anti-cytotoxic T-lymphocyte antigen 4, anti-programmed death-1 (PD-1), and anti-programmed death-ligand 1 (PD-L1) monoclonal antibodies. The toxicity profile of ICIs is unique in that they often trigger the development of immune-related adverse effects (irAEs). Commonly reported irAEs include colitis, hepatitis, endocrinopathies, dermatitis, thyroiditis, and pneumonitis; however, virtually all organ systems can develop immune toxicities.^{1,2} Neurologic irAEs include neuropathy, myelopathy, Guillain-Barré syndrome, meningitis, myasthenia gravis, and encephalitis and occur in less than 1% of patients.^{1,3} Immune-mediated encephalitis is especially uncommon and occurs in less than 0.2% of patients.⁴ We describe a case of anti-PD-1 antibody-related

immune-mediated cerebellar encephalitis. To our knowledge, this is the first described case of ICI-associated immune-mediated cerebellar encephalitis in the literature.

CASE STUDY

A 20-year-old white man with stage IVB primary refractory Hodgkin lymphoma that progressed despite 3 previous therapies (doxorubicin-bleomycin-vinblastine-dacarbazine [ABVD], ifosfamide-carboplatin-etoposide [ICE], and brentuximab vedotin) was treated with nivolumab 3 mg/kg every 2 weeks. He presented 13 days after his third cycle of nivolumab to an emergency department with 1 day of bilateral stabbing headache, diplopia, confusion, nausea, and vomiting. He did not have any history of infection. On examination he was afebrile and hemodynamically stable. Neurologic examination was notable for ataxia and dysmetria. Meningeal signs were absent. Initial head computed tomography showed cerebellar

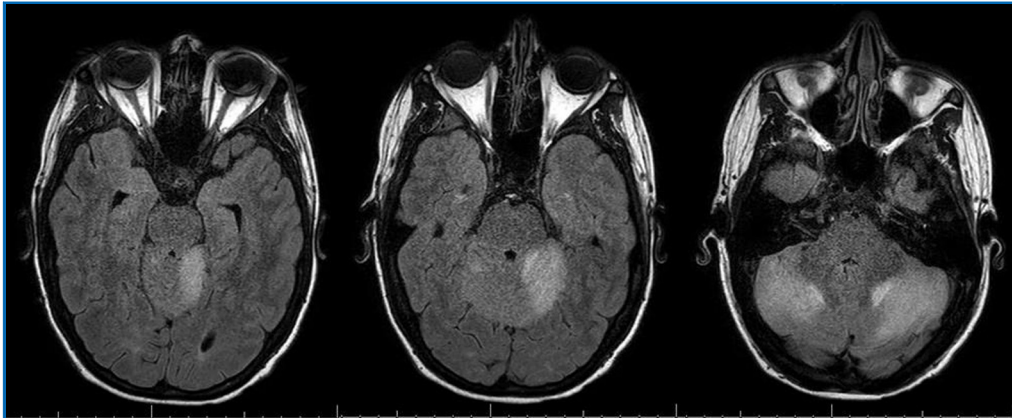


FIGURE 1. Axial T2 FLAIR MRI of patient on day 6 of hospitalization and day 4 of dexamethasone therapy. FLAIR = fluid-attenuated inversion recovery; MRI = magnetic resonance imaging.

edema. Brain magnetic resonance imaging (MRI) showed a diffusely edematous cerebellum with patchy enhancement, signs of early tonsillar herniation, and early hydrocephalus. Antibiotics were initiated for possible meningitis. Initial lumbar puncture was unsuccessful. After consultation with his primary oncologist, high-dose dexamethasone (8 mg every 6 hours) was initiated because of a high possibility of immune-mediated encephalitis.

By day 6, his nausea and vomiting had resolved. He continued to have mild residual ataxia of his extremities (left greater than right), mild dysmetria, and dizziness. Repeated MRI on day 6 showed persistent but improved bilateral cerebellar hemispheric edema with mild cerebellar leptomeningeal enhancement (Figure 1). Later, cerebrospinal fluid (CSF) examination revealed normal glucose (73 mg/dL), elevated protein (161 mg/dL), and lymphocytic pleocytosis (white blood cells, 31/ μ L; 94% lymphocytes, 6% monocytes). Cryptococcal antigen studies, herpes simplex virus polymerase chain reaction, and routine CSF cultures yielded negative results. The CSF flow cytometry results were normal. The patient was discharged on day 8 and dexamethasone was tapered over 4 weeks. At 6-week follow-up, the patient's symptoms had essentially resolved except for mild diplopia. The brain MRI at 6-week follow-up showed near resolution of cerebellitis with subtle persistent enhancement within the cerebellar sulci (Figure 2). Positron emission tomography at 6-week follow-up showed a partial response. The cerebellitis was believed to represent an

immune-mediated encephalitis related to anti–PD-1 therapy; therefore, nivolumab was discontinued with a plan to begin an alternative therapy at next follow-up.

DISCUSSION

We describe a case of acute cerebellar encephalitis that developed after exposure to nivolumab used to treat primary refractory Hodgkin lymphoma. Although causality cannot be proven without biopsy, several clinical features suggest that his presentation was related to ICI exposure, including the timing of his symptoms, his rapid improvement with corticosteroids, and negative results of infectious work-up. Etiologies that must be considered in the differential diagnosis of ICI-related immune-mediated cerebellar encephalitis include paraneoplastic cerebellar degeneration (PCD), acute infectious cerebellitis, postinfectious cerebellitis, gliadin-associated cerebellar ataxia, glutamic acid decarboxylase (GAD)-associated cerebellar ataxia, thiamine deficiency, alcohol abuse, and cerebellar metastases.⁵ Thiamine deficiency and alcohol abuse were excluded on the basis of history. Brain metastases were excluded on the basis of absence of localized lesion on brain MRI and normal findings on CSF flow cytometry. Paraneoplastic cerebellar degeneration, gliadin- and GAD-associated cerebellar ataxia, and infectious and postinfectious cerebellitis were all considerations in our patient's case.

Paraneoplastic cerebellar degeneration has been well described in Hodgkin lymphoma,

Download English Version:

<https://daneshyari.com/en/article/8924751>

Download Persian Version:

<https://daneshyari.com/article/8924751>

[Daneshyari.com](https://daneshyari.com)