




Available online at
ScienceDirect
www.sciencedirect.com

Elsevier Masson France
EM|consulte
www.em-consulte.com/en



Case Report

Agressive pediatric myofibromatosis in a two-year-old child

C. Letelier^a, M. Gunther^a, A. Alarcon^{b,c}, P. Vera^d, E. Kakarieka^e, R. Pantoja^{b,c,*}

^a Department of buccal and maxillo-facial surgery, faculty of dentistry, university of Chile, Chile

^b Department of buccal and maxillo-facial surgery, faculty of dentistry, university of Chile, Chile

^c Maxillo-facial surgery service, San Borja-Arriarán clinical hospital, Chile

^d Service of pediatric surgery, San Borja-Arriarán clinical hospital, Santiago, Chile

^e Anatomic pathology service, San Borja-Arriarán clinical hospital, Santiago, Chile

ARTICLE INFO

Historique de l'article :

Received 20 July 2017

Accepted 30 November 2017

Keywords:

Aggressive myofibromatosis

Childhood

Surgery

SUMMARY

Introduction: Aggressive paediatric myofibromatosis is an autosomal recessive disease characterized by fibroblastic proliferation from cells originated in muscle-aponeurotic tissue. Its etiology is unknown, and the average age of the reported cases is 7 years old. The tumor exhibits rapid painless growth and appears attached to muscle tissue and/or bone. The treatment of choice is conservative surgical excision despite of early relapses has been reported.

Observation: A 2-year-old patient, with no morbid history, presented with a large swelling in the left submandibular region, firm, neither defined limits nor inflammatory characteristics. Its size doubled 2 months after an incisional biopsy. CT images showed great compromise of the left mandibular body with expanded and thinned cortical bone. The MRI showed extension towards the pharynx. Histopathological findings were elongated fibroblastic and ovoid cells arranged in bundles and fascicles within fibromyxoid stroma, an image consistent with the diagnosis. The treatment consisted in a conservative exeresis of the tumor, preserving the jaw. Control 1 year after surgical removal shows no signs of relapse and the mandibular structure has been restored.

Discussion: The large size of the lesion and bone involvement at such an early age evidenced a very aggressive lesion, however, supported by a previous biopsy, we performed a conservative treatment, which only caused the loss of a dental germ, impossible to take off from the intraosseous tumor. The control of this type of lesions requires a longer follow-up.

© 2017 Elsevier Masson SAS. All rights reserved.

1. Introduction

Aggressive paediatric fibromatosis is a recessive autosomal disease characterized by the spread of fibroblastic cells from muscle tissue, or aponeurosis [1]. Of unknown origin, its onset has been associated with traumatic, hormonal and genetic factors [2]. It is far more common in boys than in girls, by a factor of 18 to 1, and the average age of the reports is seven years [2].

Such tumours have been described in the neck, the parotid, submandibular region, lateral orbit, and the outer ear, among others. They grow quickly, are painless and normally adhere to muscle and/or bone tissue. The lesion can obstruct the airway if it grows toward the midline and reaches the oropharynx [3]. It is a relatively rare condition whose occurrence is 0.2–0.4 cases per 100,000, of which 12% are in the head and neck [4].

* Corresponding author at: Department of buccal and maxillo-facial surgery, faculty of dentistry, university of Chile, Chile.

E-mail address: profepantoja@gmail.com (R. Pantoja).

<https://doi.org/10.1016/j.jormas.2017.11.018>

2468-7855/© 2017 Elsevier Masson SAS. All rights reserved.

2. Observation

A two-year-old boy without a medical history was brought to us for consultation due to significant sub-mandibular swelling, painless and disfiguring, on the left side that had evolved over the last few months and which had doubled in volume over the last two months, since an incisional biopsy was carried out for diagnostic purposes. The histological diagnosis was fibromatosis (Fig. 1) The MRI images reveals a large tumour enveloping the left mandibular body, invading its left lingual side, passing along the back side of the ascending ramus to the vicinity of the inner lower pharynx, deforming the upper and lower hyoids on the left (Figs. 2 and 3) The lingual cortical plate of the mandibular bone structure was destroyed and the vestibular bone was worn and deformed, which led us to fear a fracture during surgery. The CT images of the chest, abdomen and pelvis did not reveal any other tumour sites.

We adapted an osteosynthesis plate using a 3D print of the mandible and small acrylic splints to fix it in the same position in the intraoperative period and to reinforce the structure during

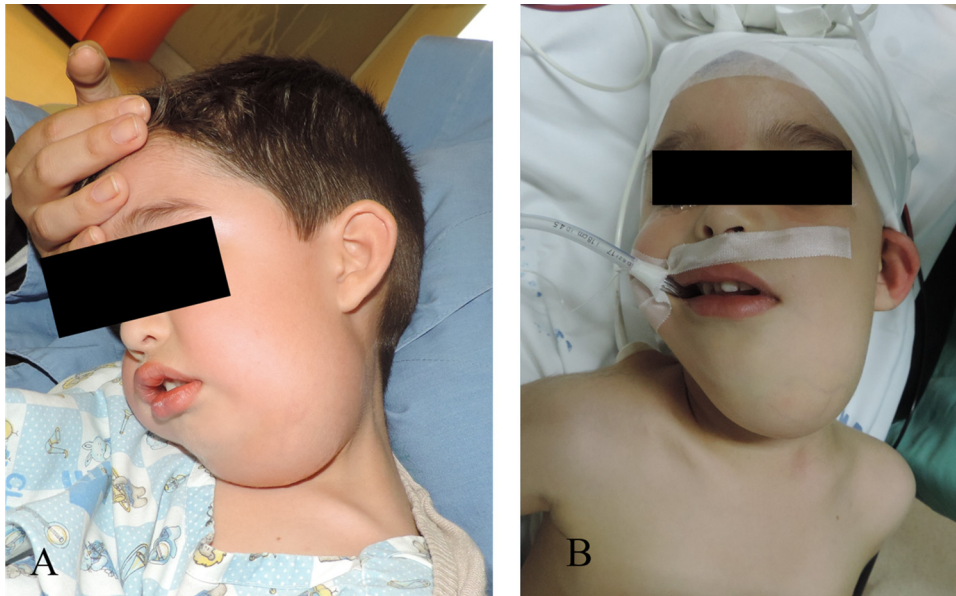

Fig. 1. A. Lateral view. B. Frontal view, two weeks later.

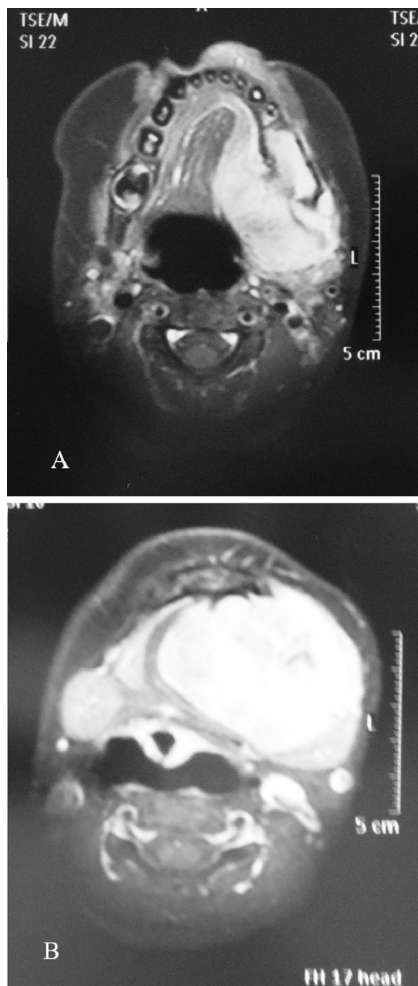


Fig. 2. A. NMR Picture, showing the tumor in the mandibular body. B. Lower image, passing by sub-mandibular space.

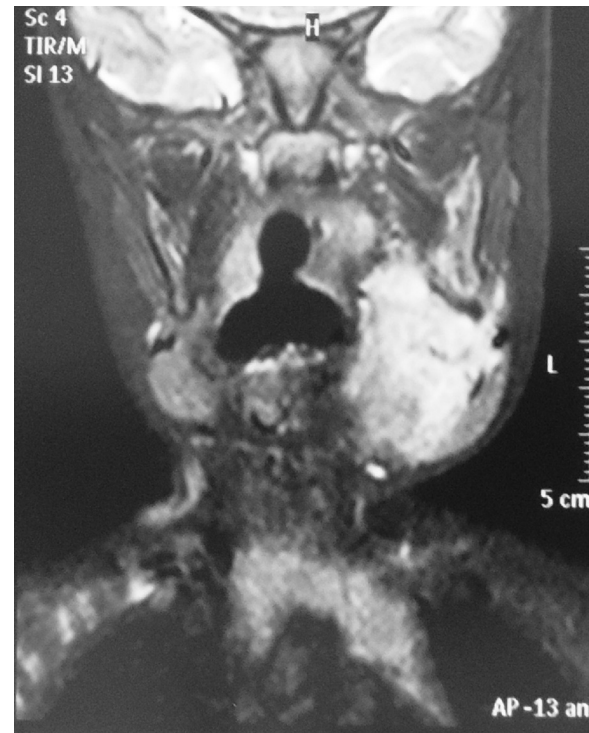


Fig. 3. Frontal view.

curettage (Fig. 4). The intervention was performed under general anaesthesia and we used a cervical approach to expose the most superficial part of the tumour, which presented a cleavage plane. We were forced to resect the superficial part of the tumour to reach the mandibular body (Fig. 5). We then exposed the mandible and resected the deep sub-mandibular part, which was well-encapsulated. Lastly, we placed the osteosynthesis plate and removed the tumour from the mandibular body, where a dental germ came out attached to the lesion (Fig. 6).

Download English Version:

<https://daneshyari.com/en/article/8924801>

Download Persian Version:

<https://daneshyari.com/article/8924801>

[Daneshyari.com](https://daneshyari.com)