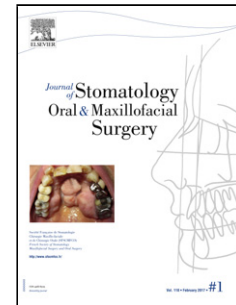


Accepted Manuscript

Title: Carcinoma cuniculatum of the lip: A case REPORT

Author: Thibouw François Anna Hallier Levasseur Julie
Mondoloni Céline Aubriot-Lorton Marie-Hélène Zwetyenga
Narcisse



PII: S2468-7855(18)30034-X
DOI: <https://doi.org/doi:10.1016/j.jormas.2018.01.006>
Reference: JORMAS 145

To appear in:

Received date: 13-9-2017
Revised date: 29-12-2017
Accepted date: 29-1-2018

Please cite this article as: Thibouw François Anna Hallier Levasseur Julie Mondoloni Céline Aubriot-Lorton Marie-Hélène Zwetyenga Narcisse Carcinoma cuniculatum of the lip: A case REPORT (2018), <https://doi.org/10.1016/j.jormas.2018.01.006>

This is a PDF file of an unedited manuscript that has been accepted for publication. As a service to our customers we are providing this early version of the manuscript. The manuscript will undergo copyediting, typesetting, and review of the resulting proof before it is published in its final form. Please note that during the production process errors may be discovered which could affect the content, and all legal disclaimers that apply to the journal pertain.

CARCINOMA CUNICULATUM OF THE LIP: A CASE REPORT

Thibouw François (1), Anna Hallier (1), Levasseur Julie (1), Mondoloni Céline (1), Aubriot-Lorton Marie-Hélène (2), Zwetyenga Narcisse (1,3)

(1) CHU Dijon, Department of Oral and Maxillofacial Surgery, Department of Plastic Reconstructive and Hand Surgery, Centre Hospitalier Universitaire, Boulevard de Lattre-de-Tassigny, 21000 Dijon, France

(2) CHU Dijon, Department of Pathology, Centre Hospitalier Universitaire, Boulevard Jeanne d'Arc, 21079 Dijon, France.

(3) University of Burgogne-Franche-Comté, Inserm 1231- Lipids Nutrition Cancer- Team NuTox Boulevard Jeanne-d'Arc, 21000 Dijon, France

Corresponding author: francois.thibouw@gmail.com

CARCINOMA CUNICULATUM OF THE LIP: A CASE REPORT**ABSTRACT**

Carcinoma cuniculatum, a very well differentiated sub-type of epidermoid carcinoma, is a rare invasive tumor with a low risk of metastasis. It principally affects the lower limbs, notably the soles of the feet. Facial involvement is exceptional.

A case of a patient with carcinoma cuniculatum of the lower lip is presented and diagnostic difficulties of head locations of this tumor, as well as their management are discussed.

Key words: carcinoma cuniculatum, lip, head and neck

Download English Version:

<https://daneshyari.com/en/article/8924803>

Download Persian Version:

<https://daneshyari.com/article/8924803>

[Daneshyari.com](https://daneshyari.com)