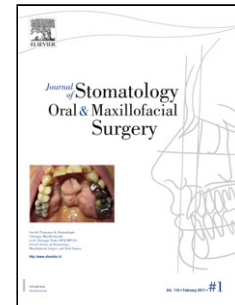


Accepted Manuscript

Title: Conservative management of an atypical intra-sinusal ossifying fibroma associated to an aneurysmal bone cyst

Author: Ryan Saad Jean-Christophe Lutz Riehm Sophie Marcellin Luc Catherine-Isabelle Gros Fabien Bornert



PII: S2468-7855(17)30193-3
DOI: <https://doi.org/doi:10.1016/j.jormas.2017.10.015>
Reference: JORMAS 108

To appear in:

Received date: 24-7-2017
Accepted date: 10-10-2017

Please cite this article as: Ryan SaadJean-Christophe LutzRiehm SophieMarcellin LucCatherine-Isabelle GrosFabien Bornert Conservative management of an atypical intra-sinusal ossifying fibroma associated to an aneurysmal bone cyst (2017), <https://doi.org/10.1016/j.jormas.2017.10.015>

This is a PDF file of an unedited manuscript that has been accepted for publication. As a service to our customers we are providing this early version of the manuscript. The manuscript will undergo copyediting, typesetting, and review of the resulting proof before it is published in its final form. Please note that during the production process errors may be discovered which could affect the content, and all legal disclaimers that apply to the journal pertain.

Title : Conservative management of an atypical intra-sinusal ossifying fibroma associated to an aneurysmal bone cyst.

Running Title : Intra-sinusal ossifying fibroma associated to an aneurysmal bone cyst.

Type of article : Case report

Authors : Ryan Saad (DDS, resident)^{1,2}, Jean-Christophe Lutz (MD, Associate Professor)^{3,4,5}, Riehm Sophie (MD)⁶, Marcellin Luc (MD)⁷, Catherine-Isabelle Gros (DDS, PhD, Associate Professor)^{1,5,8}, Fabien Bornert (DDS, PhD, Associate Professor)^{1,2,5}

Affiliations :

1. University of Strasbourg, Dental Faculty, 8 rue Sainte Elisabeth, F-67000 Strasbourg
2. Oral Surgery and Oral Medicine unit, Dental Clinic, Hôpital Civil, University Hospital of Strasbourg, 1 place de l'Hôpital, F-67000 Strasbourg
3. University of Strasbourg, Faculty of Medicine, 4 rue Kirschleger, F-67000 Strasbourg.
4. Stomatology Maxillo-facial and Plastic Surgery Department, Hôpital Civil, University Hospital of Strasbourg, 1 place de l'Hôpital, F-67000 Strasbourg
5. INSERM (French National Institute of Health and Medical Research), "Osteoarticular and Dental Regenerative Nanomedicine" laboratory, <http://www.regmed.fr>, UMR 1109, Faculté de Médecine, FMTS, F-67085 Strasbourg Cedex.
6. Medical Imaging Unit, Hôpital de Hautepierre, University Hospital of Strasbourg, 1 place de l'Hôpital, F-67000 Strasbourg
7. Pathology Department, Hôpital de Hautepierre, University Hospital of Strasbourg, 1 place de l'Hôpital, F-67000 Strasbourg
8. Dentomaxillofacial radiology unit, Dental Clinic, Hôpital Civil, University Hospital of Strasbourg, 1 place de l'Hôpital, F-67000 Strasbourg

MeSH : ossifying fibroma, aneurysmal bone cyst, maxillary sinus

Corresponding author :

Fabien Bornert, DDS, PhD: fabien.bornert@chru-strasbourg.fr, +33686431385

Oral Surgery and Oral Medicine Unit, Dental Clinic, Hôpital Civil, University Hospital of Strasbourg, 1 place de l'Hôpital, F-67000 Strasbourg, France.

No conflict of interest

Abstract (119 words)

Ossifying fibroma (OF) is a benign fibro-osseous lesion mainly occurring in young adults and seems to originate from the periodontal ligament. Aneurysmal Bone Cyst (ABC) is a benign intraosseous lesion characterized by blood filled spaces of various sizes. These two lesions can specifically affect the jaws and

Download English Version:

<https://daneshyari.com/en/article/8924826>

Download Persian Version:

<https://daneshyari.com/article/8924826>

[Daneshyari.com](https://daneshyari.com)