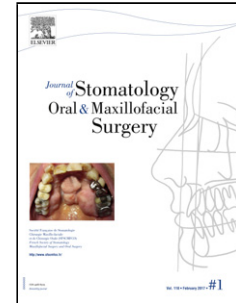


## Accepted Manuscript

Title: Benign symmetric lipomatosis with lingual involvement: Case report and literature review.

Author: Miguel Mayo Yáñez Nicolás González Poggioli  
Mercedes Álvarez-Buylla Blanco Jesús Herranz  
González-Botas Alejandro Barreiro Noya



PII: S2468-7855(17)30202-1  
DOI: <https://doi.org/doi:10.1016/j.jormas.2017.11.006>  
Reference: JORMAS 116

To appear in:

Received date: 8-12-2016  
Revised date: 6-9-2017  
Accepted date: 1-11-2017

Please cite this article as: Miguel Mayo Yáñez Nicolás González Poggioli Mercedes Álvarez-Buylla Blanco Jesús Herranz González-Botas Alejandro Barreiro Noya Benign symmetric lipomatosis with lingual involvement: Case report and literature review. (2017), <https://doi.org/10.1016/j.jormas.2017.11.006>

This is a PDF file of an unedited manuscript that has been accepted for publication. As a service to our customers we are providing this early version of the manuscript. The manuscript will undergo copyediting, typesetting, and review of the resulting proof before it is published in its final form. Please note that during the production process errors may be discovered which could affect the content, and all legal disclaimers that apply to the journal pertain.

## TITLE:

Benign symmetric lipomatosis with lingual involvement: Case report and literature review.

- Miguel Mayo Yáñez, MD. Corresponding author.

o Resident Otolaryngologist. Xerencia de Xestión Integrada A Coruña

- Nicolás González Poggioli, MD.

o Deputy Otolaryngologist. Xerencia de Xestión Integrada A Coruña

- Mercedes Álvarez-Buylla Blanco, MD. PhD.

o Deputy Otolaryngologist. Xerencia de Xestión Integrada A Coruña

- Jesús Herranz González-Botas, MD. PhD.

o Section Head Otolaryngologist. Xerencia de Xestión Integrada A Coruña

o Professor of Otolaryngology. School of Medicine. Universidad de Santiago de Compostela

## CORRESPONDENCE:

Alejandro Barreiro Noya, nº 3. Piso 4º IZQ. CP. 15006. A Coruña. España.

miguelmmy@gmail.com

Telephone: +34 639506535

Stomatology Oral and Maxillofacial Surgery

Manuscript Draft

Manuscript Number: REVSTO-D-16-00145R2

Title: Benign symmetric lipomatosis with lingual involvement: Case report and literature review

Article Type: Case Report

Keywords: Multiple symmetrical lipomatosis; Dysphagia; Tongue diseases; Glossectomy

Corresponding Author: Dr. Miguel Mayo Yáñez, MD

Corresponding Author's Institution: Xerencia de Xestión Integrada A Coruña

First Author: Miguel Mayo Yáñez

Order of Authors: Miguel Mayo Yáñez; Nicolás González Poggioli; Mercedes Álvarez-Buylla Blanco; Jesús Herranz González-Botas

Abstract: Benign symmetrical lipomatosis (BSL) is a rare disorder characterized by diffuse, multiple, symmetric and non-encapsulated fat masses generally localized in the face, neck and upper trunk. An uncommon case of lingual affliction in BSL, presented with macroglossia, sleep apnea, dysphagia and dysarthria is described. Bilateral partial glossectomy was performed, with an improvement in initial symptoms one year after surgery. Only seven other BSL cases with lingual involvement have been reported in the literature. This case report and literature review highlights that BSL with lingual affliction is extremely rare, almost exclusive for BSL Type I and affects predominantly middle-aged males from mediterranean countries. Surgical treatment with unilateral or bilateral partial glossectomy usually restores normal tongue function, but must be accompanied with a postoperative follow up to assure that recurrence does not occur.

Download English Version:

<https://daneshyari.com/en/article/8924830>

Download Persian Version:

<https://daneshyari.com/article/8924830>

[Daneshyari.com](https://daneshyari.com)