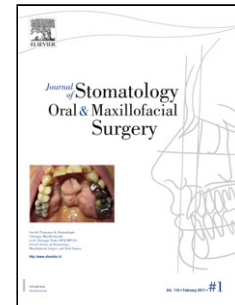


## Accepted Manuscript

Title: Isolated unilateral temporalis muscle hypertrophy: first case in an 8-year-old boy and review

Author: Narcisse Zwetyenga Anna Hallier Marine Girodon  
Julie Levasseur Ludwig Loison-Robert Vivien Moris



PII: S2468-7855(17)30188-X  
DOI: <https://doi.org/doi:10.1016/j.jormas.2017.10.010>  
Reference: JORMAS 103

To appear in:

Received date: 2-10-2016  
Revised date: 16-8-2017  
Accepted date: 2-10-2017

Please cite this article as: Narcisse ZwetyengaAnna HallierMarine GirodonJulie LevasseurLudwig Loison-RobertVivien Moris Isolated unilateral temporalis muscle hypertrophy: first case in an 8-year-old boy and review (2017), <https://doi.org/10.1016/j.jormas.2017.10.010>

This is a PDF file of an unedited manuscript that has been accepted for publication. As a service to our customers we are providing this early version of the manuscript. The manuscript will undergo copyediting, typesetting, and review of the resulting proof before it is published in its final form. Please note that during the production process errors may be discovered which could affect the content, and all legal disclaimers that apply to the journal pertain.

# **Isolated unilateral temporalis muscle hypertrophy: first case in an 8-year-old boy and review**

<sup>1,2</sup> Narcisse Zwetyenga, <sup>1</sup> Anna Hallier MD, <sup>1</sup> Marine Girodon, <sup>1</sup> Julie Levasseur, <sup>3</sup> Ludwig Loison-Robert <sup>1</sup> Vivien Moris MD

<sup>1</sup> CHU Dijon, Department of Oral and Maxillofacial Surgery, Department of Plastic Reconstructive and Hand Surgery - Centre Hospitalier Universitaire, Boulevard de Lattre de Tassigny F-21000 Dijon, France

<sup>2</sup> University of Bourgogne Franche-Comté, Lipids Nutrition Cancer team NuTox UMR866, Boulevard Jeanne d'Arc F-21000 Dijon, France

<sup>3</sup> Department of Oral Medicine and Dental Surgery, Boulevard de Lattre de Tassigny F-21000 Dijon, France

Corresponding author: nzwetyenga@gmail.com

\*. Title/Authors/Affiliations

## **Abstract**

## **Introduction**

Isolated Unilateral Temporalis Muscle Hypertrophy (IUTMH) was first described in 1990, and few cases have been published since then. This disease occurs mainly in adults. There is no clear etiology of IUTMH, but bruxism is one of the risk factors. Only two cases have been described before the age of 20 years. To our knowledge, no cases have been described in persons younger than 15 years old. We report the first case of IUTMH in an 8-year-old and review the literature.

## **Material and methods**

This section is separated into 3 parts: 1- search for and description of clinical cases of IUTMH in our department; 2- literature search to find similar cases; 3- data analysis of all cases found.

## **Results**

Ten patients, including our case, were found over a period of 23 years: five females and five males with a mean age of 32.8 years. One patient was 15 years old. Time between onset and diagnosis was 16.7 months. Half of the patients reported pain and three had experienced bruxism. Most of the patients had non-surgical treatment. One patient evolved favorably with no treatment. One recurrence occurred 10 years later.

## **Discussion**

Download English Version:

<https://daneshyari.com/en/article/8924857>

Download Persian Version:

<https://daneshyari.com/article/8924857>

[Daneshyari.com](https://daneshyari.com)