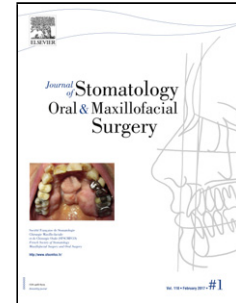


Accepted Manuscript

Title: Alveolar soft part sarcoma metastatic to the mandible: a report and review of literature

Author: Scott M. Peters Michael A. Perrino Angela J. Yoon
Elizabeth M. Philipone



PII: S2468-7855(17)30121-0
DOI: <http://dx.doi.org/doi:10.1016/j.jormas.2017.07.004>
Reference: JORMAS 76

To appear in:

Received date: 27-1-2017
Revised date: 26-5-2017
Accepted date: 11-7-2017

Please cite this article as: Scott M. Peters Michael A. Perrino Angela J. Yoon Elizabeth M. Philipone Alveolar soft part sarcoma metastatic to the mandible: a report and review of literature (2017), <http://dx.doi.org/10.1016/j.jormas.2017.07.004>

This is a PDF file of an unedited manuscript that has been accepted for publication. As a service to our customers we are providing this early version of the manuscript. The manuscript will undergo copyediting, typesetting, and review of the resulting proof before it is published in its final form. Please note that during the production process errors may be discovered which could affect the content, and all legal disclaimers that apply to the journal pertain.

Alveolar soft part sarcoma metastatic to the mandible: a report and review of literature

Scott M. Peters, DDS^a, Michael A. Perrino, DDS, MD^b, Angela J. Yoon, DDS, MAMsc, MPH^c, Elizabeth M. Philipone, DMD^{d*}

^aResident, Division of Oral and Maxillofacial Pathology, Columbia University College of Dental Medicine, New York, NY

^bAssistant Professor, Division of Oral and Maxillofacial Surgery, Columbia University College of Dental Medicine, New York, NY

^cProgram Director, Division of Oral and Maxillofacial Pathology, Columbia University College of Dental Medicine, New York, NY

^dAssociate Professor, Division of Oral and Maxillofacial Pathology, Columbia University College of Dental Medicine, New York, NY

*Corresponding Author:

Dr. Elizabeth M. Philipone, DMD
Columbia University Medical Center
630 West 168th Street
PH15W-1562
New York, NY 10032
ep2464@columbia.edu

Word Count: Abstract 105; Complete manuscript 2178

Number of references: 15

Number of tables: 0

Number of figures: 5

Number of supplementary elements: 0

Disclosure of Potential Conflicts of Interest

There are no conflicts of interest declared by any other author. The study received no commercial funding.

Abstract

Alveolar soft part sarcoma (ASPS) is a rare neoplasm constituting less than 1% of all soft tissue sarcomas. It tends to occur in the deep soft tissues of the lower extremities, however approximately 5-12% of cases are primary to the head and neck region. ASPS metastatic to the oral cavity is rare, with only four documented cases in the literature. Here, we present the case of a 29-year-old woman with ASPS metastatic to the mandible. To the best of our knowledge, this represents only the 5th documented case

Download English Version:

<https://daneshyari.com/en/article/8924882>

Download Persian Version:

<https://daneshyari.com/article/8924882>

[Daneshyari.com](https://daneshyari.com)