

## Accepted Manuscript

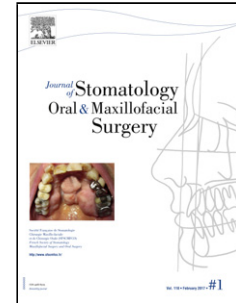
Title: Completely Exposed Nasal Bone

Author: Anshul Rai Anuj Jain Manal Khan

PII: S2468-7855(17)30140-4

DOI: <http://dx.doi.org/doi:10.1016/j.jormas.2017.08.003>

Reference: JORMAS 79



To appear in:

Received date: 23-5-2017

Accepted date: 8-8-2017

Please cite this article as: Anshul Rai Anuj Jain Manal Khan Completely Exposed Nasal Bone (2017), <http://dx.doi.org/10.1016/j.jormas.2017.08.003>

This is a PDF file of an unedited manuscript that has been accepted for publication. As a service to our customers we are providing this early version of the manuscript. The manuscript will undergo copyediting, typesetting, and review of the resulting proof before it is published in its final form. Please note that during the production process errors may be discovered which could affect the content, and all legal disclaimers that apply to the journal pertain.

1. Anshul Rai

Department of Trauma and Emergency Medicine,  
All India Institute of Medical; Sciences,  
Bhopal, Madhya Pradesh, India.

2. Anuj Jain

Department of Trauma and Emergency Medicine,  
All India Institute of Medical; Sciences,  
Bhopal, Madhya Pradesh, India.

3. Manal Khan

Department of Burns and Plastic Surgery  
All India Institute of Medical; Sciences,  
Bhopal, Madhya Pradesh, India.

**Corresponding Author:**

Anuj Jain

Email address: dranujsinghvi@gmail.com

**Key Words:**

Osteomyelitis; Nasal Bone; Bone Necrosis; Definitive treatment

**. Title/Authors/Affi**

**Completely Exposed Nasal Bone**

**Case Presentation:**

A healthy, middle aged, male patient was forcefully brought to our institute by his relatives. Clinical examination revealed that the patient's nasal bone with a part of frontal bone was completely exposed (Figure 1). Patient gave no history of any systemic conditions; neither was he previously diagnosed with HIV, Hepatitis B, C, tuberculosis and sickling. On further questioning, he revealed that he was hit by a stone over the bridge of nose 8 months back during a fight, resulting in exposure of nasal bone, following which the bone remained exposed till date.

The patient was financially challenged and belonged to the tribal area and was a firm believer of traditional tribal healthcare practices and rituals. He tried all possible tribal treatments for two months but failed, following which the bone necrotized resulting in its detachment from the face (Figure 2). The patient often removes the bone himself and puts it back as an obturator to cover the underlying defect. On clinical examination, the complete nasal bone with a part of frontal bone was found to be necrotic. Removal of the necrotized bone revealed an underlying soft tissue

Download English Version:

<https://daneshyari.com/en/article/8924891>

Download Persian Version:

<https://daneshyari.com/article/8924891>

[Daneshyari.com](https://daneshyari.com)