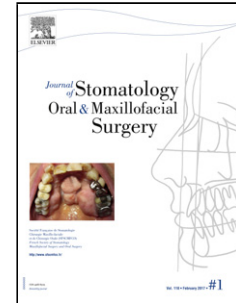


Accepted Manuscript

Title: Osteomyelitis of the jaw (with pathological fracture) following extraction of an impacted wisdom tooth. A Case Report<!--<RunningTitle>Osteomyelitis of the jaw following extraction. A case report</RunningTitle-->



Author: B. González-Navarro C. Arranz-Obispo R. Albuquerque E. Jané-Salas J. López-López

PII: S2468-7855(17)30093-9
DOI: <http://dx.doi.org/doi:10.1016/j.jormas.2017.05.003>
Reference: JORMAS 48

To appear in:

Received date: 17-3-2017
Accepted date: 21-5-2017

Please cite this article as: B. González-Navarro C. Arranz-Obispo R. Albuquerque E. Jané-Salas J. López-López Osteomyelitis of the jaw (with pathological fracture) following extraction of an impacted wisdom tooth. A Case Report<!--<RunningTitle>Osteomyelitis of the jaw following extraction. A case report</RunningTitle--> (2017), <http://dx.doi.org/10.1016/j.jormas.2017.05.003>

This is a PDF file of an unedited manuscript that has been accepted for publication. As a service to our customers we are providing this early version of the manuscript. The manuscript will undergo copyediting, typesetting, and review of the resulting proof before it is published in its final form. Please note that during the production process errors may be discovered which could affect the content, and all legal disclaimers that apply to the journal pertain.

Osteomyelitis of the jaw (with pathological fracture) following extraction of an impacted wisdom tooth. A Case Report.

Short title: Osteomyelitis of the jaw following extraction. A case report.

Authors' affiliations:

B. González-Navarro^a, C. Arranz-Obispo^b, R. Albuquerque^c, E. Jané- Salas^d, J. López-López^{e, *}.

^a DDS. Lecturer of the Master's degree in Oral Implantology, Medicine and Surgery (University of Barcelona). / IDIBELL (Barcelona, Spain) Email: beatrizgonzaleznavarro@gmail.com

^b DDS, MD, Oral and Maxillofacial Surgery Specialist (Bellvitge University Hospital). Lecturer of the Master's degree in Oral Implantology, Medicine and Surgery (University of Barcelona) / IDIBELL (Barcelona., Spain) Email: carranz@bellvitgehospital.cat

^c DDS, MS, PhD. Academic Clinical Lecturer. Birmingham Dental Hospital/ School of Dentistry, University of Birmingham (Birmingham, United Kingdom) Email: R.P.P.D.Albuquerque@bham.ac.uk

^d DDS, PhD, MD, Stomatologist. Lecturer of the Master's degree in Oral Implantology, Medicine and Surgery (University of Barcelona) / IDIBELL (Barcelona., Spain) Email: enjasa19734@gmail.com

^e DDS, PhD, MD, Stomatologist. Lecturer of the Master's degree in Oral Implantology, Medicine and Surgery (University of Barcelona) / IDIBELL (Barcelona., Spain) Email: 18575jll@gmail.com

***Corresponding autor:**

José López-López

Bellvitge University Campus, Department of Odontostomatology

Universitat de Barcelona, Pabellón de Gobierno 2^a Planta

C/ Feixa Llarga s/n 08907 L'Hospitalet de Llobregat, Barcelona (Spain)

18575jll@gmail.com

Download English Version:

<https://daneshyari.com/en/article/8924907>

Download Persian Version:

<https://daneshyari.com/article/8924907>

[Daneshyari.com](https://daneshyari.com)