Cardiovascular Pathology 37 (2018) 1–4

Contents lists available at ScienceDirect

Cardiovascular Pathology

Case Report

Three-dimensional histologic reconstruction of remnant functional accessory atrioventricular myocardial connections in a case of Wolff-Parkinson-White syndrome

Taka-aki Matsuyama [a,b,*], Ryo Haraguchi [c], Junko Nakashima [a,d], Kengo Kusano [e], Hatsue Ishibashi-Ueda [a]

[a] Department of Pathology, National Cerebral and Cardiovascular Center, Osaka, Japan
[b] Department of Legal Medicine, Showa University School of Medicine, Tokyo, Japan
[c] Graduate School of Applied Informatics, University of Hyogo, Kobe, Japan
[d] Department of Diagnostic Pathology, Kochi University School of Medicine, Kochi, Japan
[e] Division of Arrhythmia and Electrophysiology, Department of Cardiovascular Medicine, National Cerebral and Cardiovascular Center, Osaka, Japan

ARTICLE INFO

Article history:
Received 13 April 2018
Received in revised form 29 June 2018
Accepted 23 July 2018
Available online xxxx

Keywords:
Accessory pathway
Atrioventricular junction
Bundle of Kent
Histologic reconstruction
Surgical ablation
WPW syndrome

ABSTRACT

Myocardial bundles working as accessory pathways in Wolff-Parkinson-White (WPW) syndrome are generally tiny tissues, so elucidating the culprit histology of atrioventricular (AV) myocardial connections requires careful serial sectioning of the AV junction. We performed a postmortem examination of accessory AV myocardial connections in an 84-year-old man who died from pneumonia 20 years after surgical cryoablation for WPW syndrome. Three-dimensional reconstruction images of serial histologic sections revealed accessory AV connections between the atrial and ventricular myocardium in the vicinity of the cryoablation scar. The remnant myocardial bridge was 4 mm wide and made up of multiple discontinuous fibers. This case was informative in that it provided for visualization of the histologic morphology of a remnant bundle of Kent.

1. Introduction

Wolff-Parkinson-White syndrome (WPW) is a congenital abnormality that can cause paroxysmal reentrant tachycardia [1]. Anomalous atrioventricular (AV) myocardial connections that bridge the atrial and ventricular myocardia in the AV annulus, known as the bundle of Kent [2], and nodo-ventricular or -fascicular connections, known as the bundle of Mahaim [3], are responsible for appearance of the delta wave and occurrence of AV reentrant tachyarrhythmia. The delta wave, which is a specific manifestation of WPW on the 12-lead electrocardiogram, indicates the existence of an accessory conduction pathway at the AV junction, and the QRS morphology on the electrocardiogram discloses the approximate location of the accessory pathway. However, detailed histologic exploration of the myocardial connections that function as an accessory pathway has not been reported because cases of manifest WPW syndrome are not often encountered at autopsy.

Here, we describe the detailed reconstructed three-dimensional (3D) morphology of a remnant accessory pathway in an autopsied patient who had long before undergone surgical treatment of WPW syndrome.

2. Case report

The patient was an 84-year-old Japanese man for whom a delta wave had been observed on a 12-lead electrocardiogram recorded when he was 53 years of age. The wave morphology was that of right bundle branch block, type A WPW syndrome, for which the accessory pathway is in the left AV annulus [4], and the accessory connections were assumed to be located along the left side of the AV annulus (Fig. 1a). The patient experienced syncope at the age of 60, and rapid atrial fibrillation with a wide QRS complex, so-called pseudo-ventricular tachycardia, was documented (Fig. 1b). Electrophysiologic study at that time indicated multiple accessory pathways located along the left-side AV annulus and the opening of the coronary sinus. Sealy's operation (open surgical endocardial cryoablation of the AV junction) was performed [5,6]; percutaneous catheter ablation was not widely performed at the time. After the operation, the delta wave was no longer seen on the electrocardiogram (Fig. 1c), and for 20 years, there was no symptom indicative of recurrent paroxysmal tachycardia. However, when the patient was 80 years of age, a similar pre-excitation pattern (delta wave)

* Corresponding author at: Department of Legal Medicine, Showa University School of Medicine, 1-5-8 Hatanodai Shinagawa-ku, Tokyo, 142-8555, Japan. Tel.: +81 3 3784 8140; fax: +81 3 3787 6418.
E-mail address: matsu-tk@med.showa-u.ac.jp (T. Matsuyama).

https://doi.org/10.1016/j.carpath.2018.07.003
1054-8807/

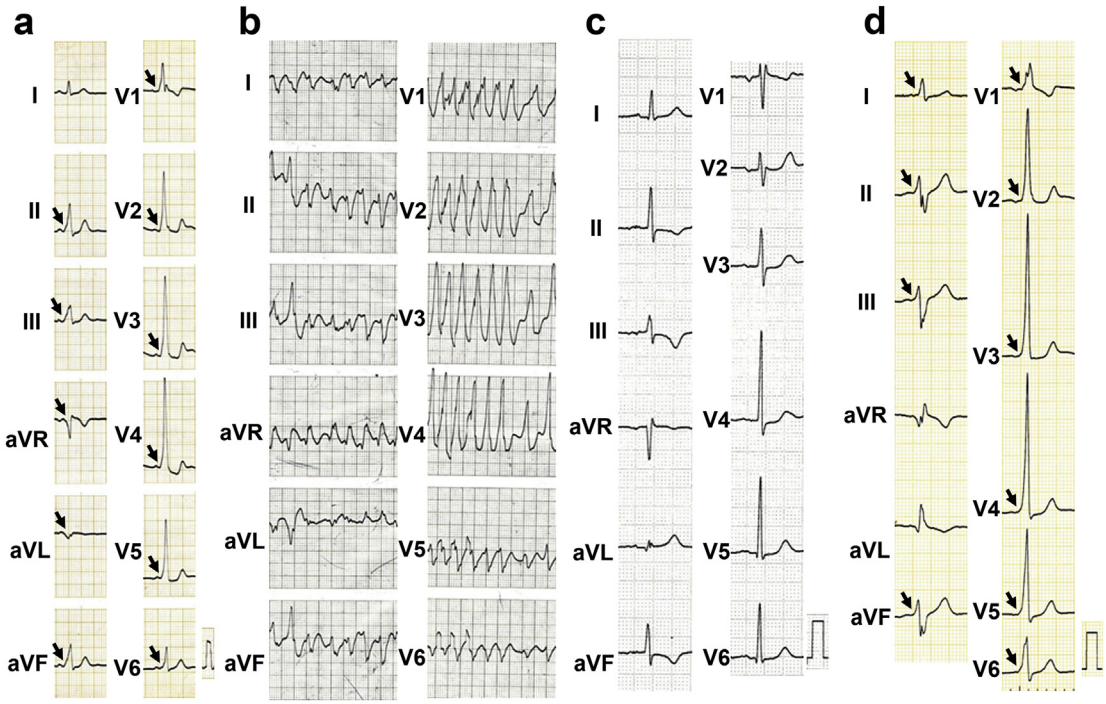

Fig. 1. Twelve-lead electrocardiograms showing the delta wave, its disappearance after surgical cryoablation, and its asymptomatic reappearance 20 years later. (a) Electrocardiogram obtained at rest when the patient was 53 years of age confirmed sinus rhythm, but a delta wave (arrow) appeared before the R wave, and the QRS complex was of the right bundle branch block type (high R wave in V1 and V2). (b) Electrocardiogram obtained just before the presyncopal attack when the patient was 60 years of age confirmed tachycardia, an irregular rapid heartbeat (150–300 bpm), and a wide QRS complex. (c) Electrocardiogram obtained after the surgical cryoablation showed absence of the delta wave. (d) Electrocardiogram obtained when the patient was in his 80s showed a delta wave similar to that seen before surgical cryoablation.

appeared on the electrocardiogram (Fig. 1d). Remnant accessory connections were assumed to exist around the surgical cryoablation scar, but no intervention was performed because no episode of tachycardia occurred. The patient died of unrelated pneumonia 4 years after confirmation of the delta wave recurrence, and autopsy was performed.

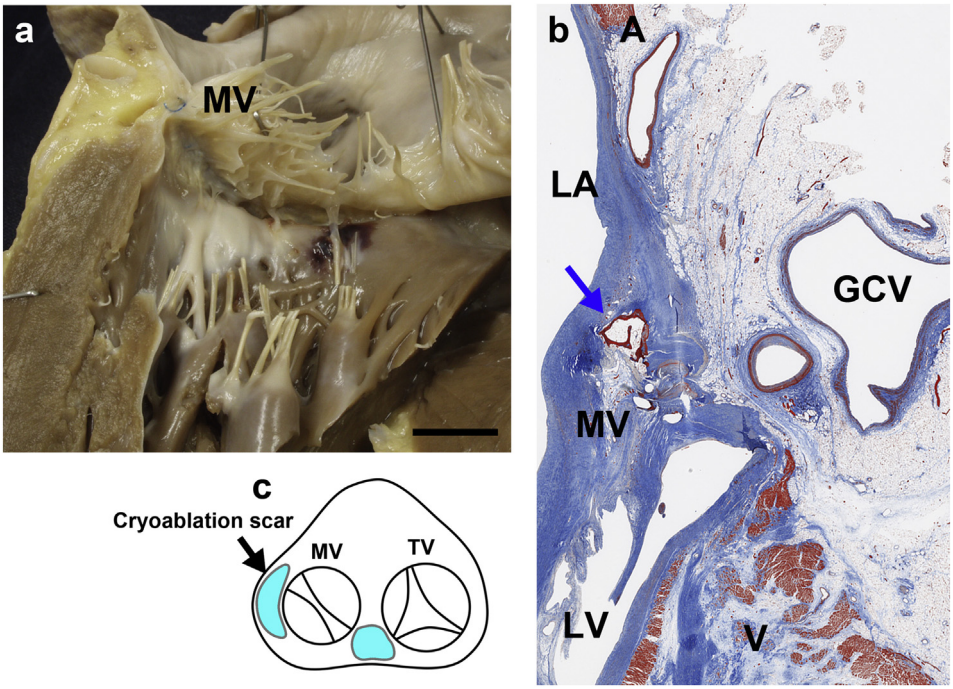

Fig. 2. Autopsy photograph of the cryoablation scar at the left atrioventricular junction, histologic section of the fibrous scar, and a diagram showing the location of the scar. (a) Macroscopically, a thick white endocardial scar was seen around the mitral valve annulus. (b) Histologic section (stained with Masson's trichrome) obtained from the center of the fibrous cryoablation scar showing that the bottom of the atrial muscle and top of the ventricular muscle around the mitral annulus were completely replaced with matured fibro-fatty tissue, and there was no muscular connection beyond the attachment of the mitral valve leaflet. Bone marrow metaplasia had thickened the attachment of the mitral valve (blue arrow). Bar=10 mm. (c) The cryoablation scar existed at the lateral mitral valve annulus and posterior atrioventricular septal junction. A, atrial muscular bundle; GCV, great cardiac vein; LA, left atrium; LV, left ventricle; MV, mitral valve; V, ventricular muscle bundle.