



Contents lists available at ScienceDirect

International Journal of Surgery Case Reports

journal homepage: www.casereports.com

Surgical treatment of a huge hepatic artery aneurysm without revascularization—Case Report

Tomohiro Imazuru*, Masateru Uchiyama, Shigefumi Matsuyama, Mitsuru Iida, Tomoki Shimokawa

Department of Cardiovascular Surgery, Teikyo University Hospital, 2-11-1, Kaga, Itabashi-ku, Tokyo, 173-8605, Japan

ARTICLE INFO

Article history:

Received 16 April 2018

Received in revised form 7 August 2018

Accepted 14 August 2018

Available online 19 August 2018

Keywords:

Hepatic artery aneurysm
A huge hepatic artery aneurysm
Open surgery
Revascularization
Cholecystectomy
Case report

ABSTRACT

INTRODUCTION: Hepatic artery aneurysms (HAA) are rare and life-threatening.

PRESENTATION OF CASE: We report a case of a 68-year-old man with a huge HAA diagnosed incidentally. Computed tomography showed a huge HAA (67–84 mm diameter). The patient underwent aneurysm resection and ligation of the common and proper hepatic arteries via laparotomy. Revascularization was not performed because intraoperative ultrasound showed pulsatile inflow to the left hepatic lobe. Postoperative cholecystitis and hepatic infarction were temporarily observed. Two months after the previous discharge, cholecystectomy was performed.

DISCUSSION: A diameter ≥ 5 cm of HAA is thought to be rare in arterial aneurysm diseases. There is no consensus in the treatment policy and treatment is selected according to the patient's condition. In this case, we selected open surgery for this patient instead of endovascular surgery due to rupture risks, irregularity and narrowness of vessel structure, and prolonged irradiation-time. If revascularization is not performed at the time of resection, open surgery with cholecystectomy is capable of preventing postoperative cholangitis after resection of HAA, and should be taken into account even if collateral circulation can be confirmed.

CONCLUSION: This case highlights the difficulty of managing HAA and provides insight into a successful surgical treatment of HAA without complete revascularization.

© 2018 The Authors. Published by Elsevier Ltd. on behalf of IJS Publishing Group Ltd. This is an open access article under the CC BY-NC-ND license (<http://creativecommons.org/licenses/by-nc-nd/4.0/>).

1. Introduction

Visceral artery aneurysms are rare and account for approximately 1–2% of all vascular diseases [1,2]. The rate of hepatic artery aneurysms (HAA), defined as an artery having at least a 50% increase in diameter compared with the expected normal diameter of the artery [3], is approximately 20% [4]. Furthermore, a huge HAA is rarer and presents as a life-threatening emergency. Because of a high risk of rupture, the aneurysm can easily cause high morbidity and mortality. We describe in line with the SCARE criteria [5] a novel case of successful surgical treatment of a huge hepatic artery aneurysm without complete revascularization in a male patient.

2. Case report

A 68-year-old man presented frequent urination that had begun 1 week before referral to our hospital. The patient had a past med-

ical history of hypertension and constipation and was a former smoker. During the initial physical examination, there was a pulsatile large mass in the epigastrium. A blood test on admission showed that all chemical parameters were within the normal range (Table 1). However, an initial computed tomographic (CT) scan revealed a huge HAA (67–84 mm diameter), which displaced the common hepatic artery in an upwards direction and the gastroduodenal artery in a forwards direction (Fig. 1a–d). In addition, although the CT scan showed that the primary arteries around the pancreas and spleen were intact, the bilateral proper hepatic arteries were narrowed. After the patient underwent laparotomy, a pulsatile and huge HAA was confirmed and narrow bilateral proper hepatic arteries were identified (Fig. 2a). The pulsation in the aneurysm disappeared where there was a cluster of the common and proper hepatic arteries (Fig. 2b). Beyond the cluster, intraoperative ultrasound (IOUS) showed pulsatile inflow to the left hepatic lobe in addition to portal blood flow. Inflow and backflow of blood to the aneurysm was confirmed (Fig. 2b). The aneurysm was resected, and the common hepatic artery and base of the proper hepatic artery were ligated; however, revascularization of the proper hepatic artery was not performed due to anatomical limitations. A liver asylum drug (glycyrrhizin acid) and prostaglandin E1 were administered from day 1, and stopped on day 10 and 14, respectively. A CT scan on day 7 showed cholecystitis and hepatic

* Corresponding author.

E-mail addresses: tomohiro.imazuru@gmail.com (T. Imazuru), mautiya@med.teikyo-u.ac.jp (M. Uchiyama), shimatsuyama@gmail.com (S. Matsuyama), m-iida@med.teikyo-u.ac.jp (M. Iida), tshimo@med.teikyo-u.ac.jp (T. Shimokawa).

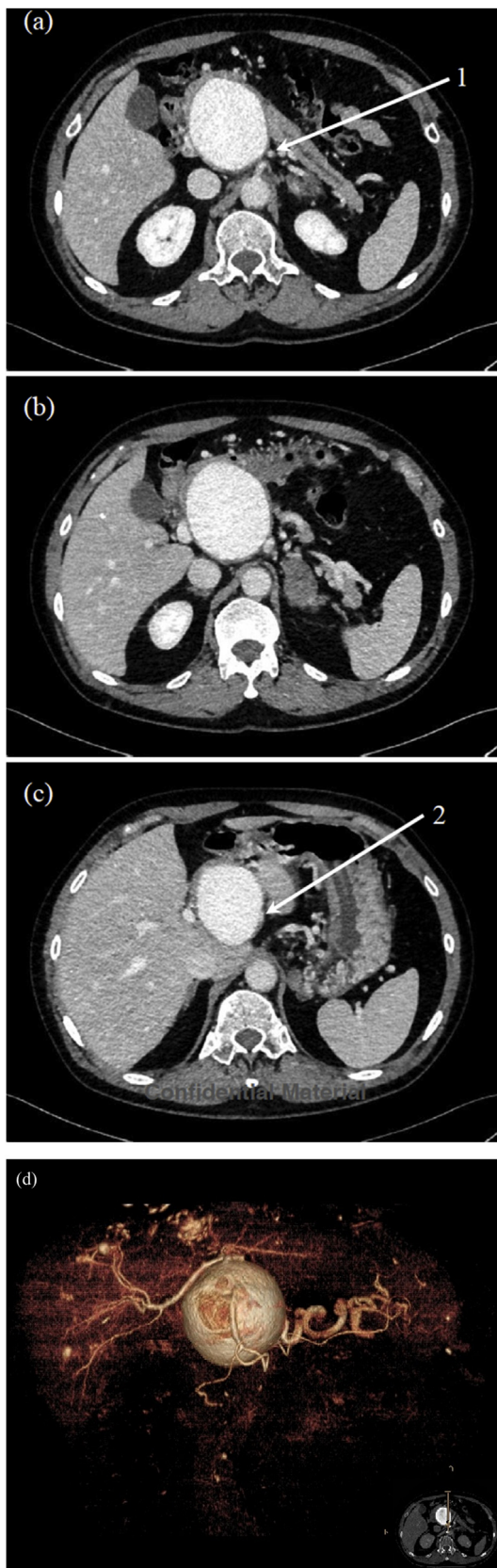


Fig. 1. Computed tomography (CT) scan before surgical operation. (a) Branch section of celiac artery, (1) common hepatic artery. (b) Maximum of a huge hepatic artery aneurysm (HAA) with 67mm~84mm. (c) The origin of a HAA, (2) the entry of common hepatic artery. (d) 3-D reconstruction CT imaging for a HAA.

infarction of the medial segment of the left hepatic lobe (Fig. 3). Percutaneous transhepatic gallbladder drainage was performed. The recovery of symptoms and postoperative blood tests progressed satisfactorily (Table 1), and he was discharged 30 days after the operation. After two months of monitoring him post discharge, open surgery for cholecystectomy as a second operation was performed from the previous upper abdominal wound. After detaching strong adhesion of intestinal tract to liver, atrophied gall bladder was confirmed and resection was performed.

3. Discussion

HAA is not a common vascular disease, for approximately only 20% of all visceral artery aneurysms are HAA [5,6]. Previous studies indicated that aneurysm rupture was observed in 21–80% of all HAA cases, and one report showed that operative mortality was 33% in the group with ruptured aneurysms and 0% in the group who underwent elective surgery [7]. For patients with a 2–5 cm diameter HAA, electing for the surgical intervention may be more controversial, while a diameter ≥ 5 cm indicates a huge HAA, and usually some surgical treatment or intervention is required. Unfortunately, over half of patients with non-ruptured HAA did not have any specific symptoms that could suspect the existence of HAA. Previous studies have indicated that 8–43% and 3–5% of all patients with non-ruptured HAA had abdominal pain (or right upper quadrant pain) and obstructive jaundice, respectively [7,8]. Although our patient with a huge HAA presented “frequent urination”, there are no studies and reports on the correlation between various symptoms, including urination, and the existence of HAA.

HAA is manifested most commonly in men and associated with arteriosclerotic diseases, hypertension, collagen vascular diseases, and fibromuscular dysplasia [9]. This patient had past medical history of hypertension, which suggested that he had an inducible factor causing HAA. Although little is known about the relationship, it is reasonable to think that past smoking history could have affected the incidence and deterioration. However, so far there have not been any reports on the etiological correlation between incidence of HAA and other diseases.

Since 1903 when Kehr et al. reported the first successful ligation of an HAA [10], many therapeutic alternatives have been reported for repairing HAA. The differences in surgical strategy are due to the complex anatomy of the visceral artery and sensitivity of the patient to hepatic ischemia [7]. Options for open surgical treatment of HAA include ligation, excision, grafting and hepatic resection [7,11]. Open surgical repair is the traditional method for treating HAA; however, many patients with visceral artery aneurysm develop severe pancreatitis and hepatobiliary disease, which may require high-risk laparotomy and eventually result in high mortality. Also, it is extremely hard to explore the aneurysm and the source of bleeding from hematoma by laparotomy for a ruptured aneurysm, and these patients may require additional operations. For these reasons, endovascular surgery is becoming increasingly popular in selected patients. In select patients with common hepatic artery aneurysms, coil embolization could be applied safely if adequate collateral circulation ensures hepatic perfusion [8]. However, one report on endovascular intervention for visceral artery aneurysm demonstrated that 30–40% of patients treated by endovascular treatment and embolization developed major complications such as late recurrence requiring open surgical repair, splenic infarction and severe pancreatitis [12]. Embolization itself can cause an increased compensatory vascular flow, which may induce progression of heterotopic aneurysm. Also, irregularity of the HAA lumen and narrowness of the outflow vessels may result in prolongation of the irradiation time. Furthermore, whether hepatic artery revascularization is needed after exclusion of HAA is also a con-

Download English Version:

<https://daneshyari.com/en/article/8945995>

Download Persian Version:

<https://daneshyari.com/article/8945995>

[Daneshyari.com](https://daneshyari.com)