

Endovascular treatment of immunoglobulin G4-related inflammatory abdominal aortic aneurysm

Kenji Sakai, MD, Taiju Watanabe, MD, PhD, and Tetsuya Yoshida, MD, PhD, Nagano, Japan

ABSTRACT

We present the case of a 51-year-old Japanese man with immunoglobulin G4-related inflammatory abdominal aortic aneurysm (AAA). A computed tomography scan showed a 60-mm AAA with inflammatory aortic wall thickening and bilateral hydronephrosis. We did not administer steroid therapy but undertook endovascular aneurysm repair. Post-operatively, inflammation of the aorta and hydronephrosis ameliorated without steroid therapy. The treatment of immunoglobulin G4-related inflammatory AAA is still debated. We achieved good clinical results with endovascular repair alone. (*J Vasc Surg Cases and Innovative Techniques* 2018;4:189-92.)

Keywords: EVAR; IgG4-related IAAA; hydronephrosis; Steroid

Inflammatory abdominal aortic aneurysm (IAAA) accounts for 2% to 10% of all abdominal aortic aneurysms (AAAs), and a significant percentage may be immunoglobulin G4 (IgG4) related.^{1,2}

Conventionally, open surgical repair has been employed for IAAA, but the surgical procedure is complicated because of dense retroperitoneal fibrosis obliterating soft tissue planes. Recently, endovascular aneurysm repair (EVAR) was undertaken for IAAA, and a good clinical result was reported.³

IgG4-related IAAA is a systemic inflammatory disease. The effectiveness of steroid therapy is reported in an article.⁴ The indications for steroid therapy are, however, still controversial. Some reports have suggested that steroid therapy may lead to an increased risk of aneurysmal rupture.¹

We undertook EVAR for IgG4-related IAAA, without steroid therapy. The clinical course was good. The patient's consent for publication was obtained.

CASE REPORT

A 51-year-old Japanese man was referred to our outpatient department with back pain persisting for a week. Physical examination showed hypertension (144/92 mm Hg) and tenderness of the right costovertebral angle. His medical history included severe diabetes mellitus, with hemoglobin A_{1c} of 12.5%, hyperlipidemia, arterial hypertension, and sleep apnea syndrome with no history of medication. He did not receive any treatment, including a medically recommended diet. He

had no allergies. He had smoked 40 cigarettes per day for 30 years. His family history was noncontributory.

A computed tomography (CT) scan showed an AAA with a diameter of 60 mm, right common iliac artery aneurysm with a diameter of 25 mm, inflammatory aortic wall thickening, and bilateral hydronephrosis (Fig 1). The inflammation of the aorta extended from the infrarenal aorta to the common iliac artery. The infrarenal aortic neck and the distal common iliac arteries remained intact from inflammation. The inflammation of the aortic adventitia was more intense at the anterior and side walls than at the posterior wall.

Laboratory investigation showed elevated C-reactive protein (CRP; 7.5 mg/dL), IgG (2152 mg/dL; normal level, 861-1747 mg/dL), and IgG4 (162 mg/dL; normal level, 4.8-105 mg/dL) levels. The serum creatinine level was 0.64 mg/dL. The white blood cell count and procalcitonin level were within normal limits. Urinalysis revealed that there was no bacteriuria. Blood cultures were negative at two sets. He had inflammation of the aortic adventitia but no evidence of bacterial infection. We diagnosed IgG4-related IAAA.

Although steroid therapy may have improved the hydronephrosis, the patient had severe diabetes mellitus. We did not administer steroids. The diameter of the aorta and sustained back pain suggested high risk of rupture. Surgical treatment was recommended.

The patient underwent EVAR with the Endurant stent graft (Medtronic Cardiovascular, Santa Rosa, Calif) and right internal iliac artery embolization with the Detach embolization coil (Cook Medical, Bloomington, Ind). The anatomy was inside instructions for use for all available stent grafts. The infrarenal neck was 21 mm wide and 28 mm in length. The right external iliac artery diameter was 7 mm, and the left common iliac artery was 21 mm. There was only minimal calcification at the level of the neck, no thrombus, and no inflammation. Common femoral artery access was obtained by cutdown. A 25-mm Endurant stent graft with iliac extensions of 24 mm (left) and 10 mm (right) was implanted successfully. The volume of estimated blood loss was 150 mL. The volume of contrast material was 110 mL. There was no endoleak intraoperatively. Post-operatively, he recovered well without complications. There was a risk of urinary tract obstruction; he underwent intravenous pyelography (IVP) just after EVAR, and on the seventh postoperative day, IVP showed patency of the bilateral urinary tract. He was discharged from the hospital after IVP.

From the Department of Cardiovascular Surgery, Hokushin General Hospital. Author conflict of interest: none.

Presented at the Ninth Conference of the German-Japanese Society of Vascular Surgery, Hiroshima, Japan, August 18-20, 2016.

Correspondence: Tetsuya Yoshida, MD, PhD, Department of Cardiovascular Surgery, Hokushin General Hospital, Nishi 1-5-63, Nakano-shi, Nagano 383-0021, Japan (e-mail: tyoshida-cvs@umin.ac.jp).

The editors and reviewers of this article have no relevant financial relationships to disclose per the Journal policy that requires reviewers to decline review of any manuscript for which they may have a conflict of interest.

2468-4287

© 2018 The Authors. Published by Elsevier Inc. on behalf of Society for Vascular Surgery. This is an open access article under the CC BY-NC-ND license (<http://creativecommons.org/licenses/by-nc-nd/4.0/>).

<https://doi.org/10.1016/j.jvscit.2018.03.012>

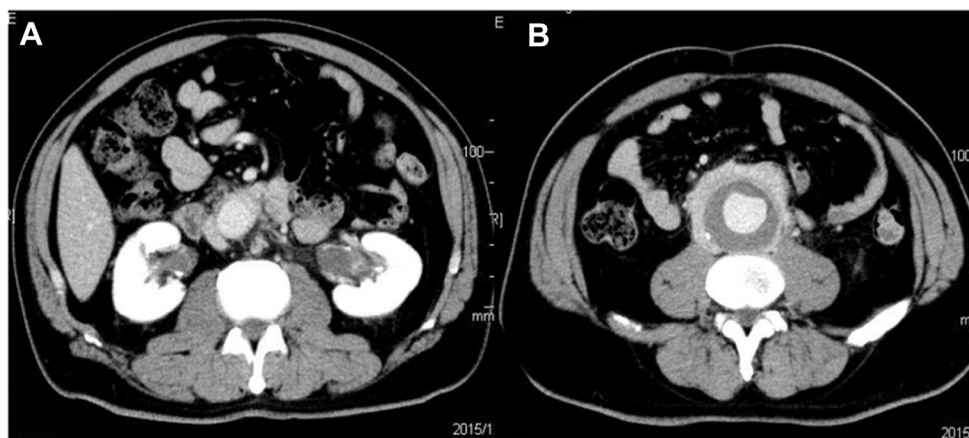


Fig 1. Computed tomography (CT) scan showing abdominal aortic aneurysm (AAA), bilateral hydronephrosis (A), and aortic wall thickening (B).

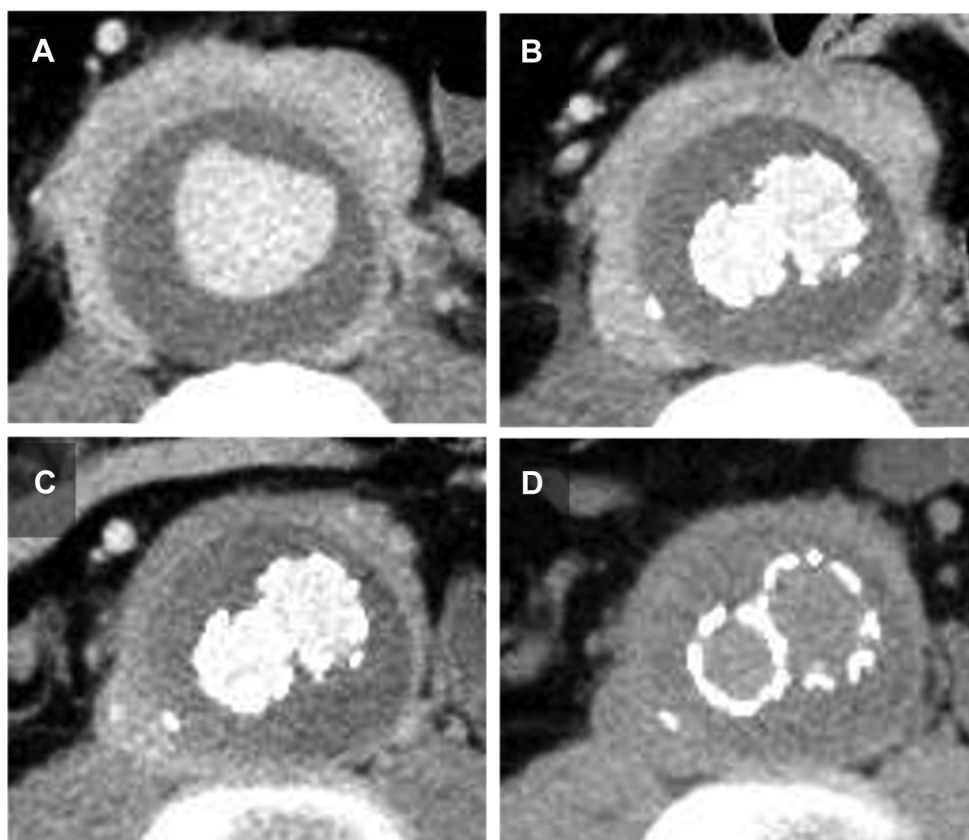


Fig 2. Follow-up computed tomography (CT) of aorta. A, Preoperative CT scan. B, One week after endovascular aneurysm repair (EVAR). C, Three months after EVAR. D, Six months after EVAR. The thickness of aortic adventitia gradually reduced.

One year later, laboratory investigation revealed decreases in the CRP level to 0.2 mg/dL, IgG level to 1942 mg/dL, and IgG4 level to 108 mg/dL, although the creatinine level remained stable. We performed follow-up CT at 1 week, 3 months, 6 months, and 1 year after EVAR. CT scan showed a regression in the thickness of the aortic adventitia (Fig 2), from 17.8 mm preoperatively to 6.4 mm at 1 year after EVAR. We did not administer steroid therapy during the follow-up period. The bilateral hydronephrosis

normalized at 6 months postoperatively (Fig 3). At the time of his most recent follow-up, the patient reported feeling well without any complaints.

DISCUSSION

IAAA accounts for 2% to 10% of all AAAs, and a significant percentage of IAAs are thought to be IgG4 related.^{1,2} IgG4-related systemic disease is a new entity

Download English Version:

<https://daneshyari.com/en/article/8946009>

Download Persian Version:

<https://daneshyari.com/article/8946009>

[Daneshyari.com](https://daneshyari.com)