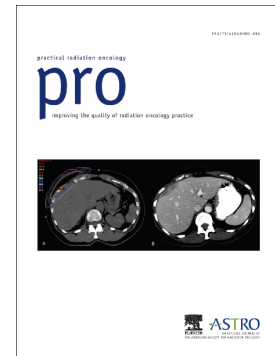


Accepted Manuscript

Case Reports: Liver Abscess After Hepatic Stereotactic Body Radiation Therapy

Meghan W. Macomber, Stephanie K. Schaub, Smith Apisarnthanarax



PII: S1879-8500(18)30068-7
DOI: doi:[10.1016/j.prro.2018.02.008](https://doi.org/10.1016/j.prro.2018.02.008)
Reference: PRRO 886

To appear in:

Received date: 5 February 2018
Accepted date: 16 February 2018

Please cite this article as: Meghan W. Macomber, Stephanie K. Schaub, Smith Apisarnthanarax , Case Reports: Liver Abscess After Hepatic Stereotactic Body Radiation Therapy. The address for the corresponding author was captured as affiliation for all authors. Please check if appropriate. Prro(2018), doi:[10.1016/j.prro.2018.02.008](https://doi.org/10.1016/j.prro.2018.02.008)

This is a PDF file of an unedited manuscript that has been accepted for publication. As a service to our customers we are providing this early version of the manuscript. The manuscript will undergo copyediting, typesetting, and review of the resulting proof before it is published in its final form. Please note that during the production process errors may be discovered which could affect the content, and all legal disclaimers that apply to the journal pertain.

Case Reports: Liver Abscess After Hepatic Stereotactic Body Radiation Therapy

Meghan W. Macomber MD, MS, Stephanie K. Schaub MD, Smith Apisarnthanarax, MD

Department of Radiation Oncology, University of Washington, Seattle, Washington, USA

Corresponding Author

Meghan Macomber

1959 NE Pacific St

Seattle, WA 98195

P: 206-598-4100

F: 206-598-3786

mwwmac@uw.edu

Presented at the 2017 Radiosurgery Society Annual Scientific Meeting in November 2-4, 2017 at

Las Vegas, NV

Running Title: Liver Abscess after SBRT

Conflicts of Interest Notification

No actual or potential conflicts of interest exist.

Download English Version:

<https://daneshyari.com/en/article/8958486>

Download Persian Version:

<https://daneshyari.com/article/8958486>

[Daneshyari.com](https://daneshyari.com)