Combined Liver-Kidney Transplantation in Children: Single-Center Experiences and Long-Term Results

M. Szymczak[a], P. Kaliciński[a], G. Kowalewski[a,*], M. Markiewicz-Kijewska[a], D. Broniszczak[a], H. Ismail[a], M. Stefanowicz[a], A. Kowalski[a], J. Rubik[b], I. Jankowska[c], B. Piątosa[d], J. Teisseyre[a], and R. Grenda[b]

[a]Department of Pediatric Surgery and Organ Transplantation; [b]Department of Nephrology, Kidney Transplantation, and Arterial Hypertension; [c]Department of Gastroenterology and Hepatology; and [d]Histocompatibility Laboratory, Children's Memorial Health Institute, Warsaw, Poland

ABSTRACT

Combined liver-kidney transplantation (CLKT) is a rare procedure in pediatric patients in which liver and kidney from 1 donor are transplanted to a recipient during a single operation. The aim of our study was to analyze indications and results of CLKT in children.

Materials and Methods. Between 1990 and 2017 we performed 722 liver transplantations in children; we performed 920 kidney transplantations in children since 1984. Among them, 25 received CLKT. Primary diagnosis was fibro-polycystic liver and kidney disease in 17 patients, primary hyperoxaluria type 1 in 6 patients, and atypical hemolytic uremic syndrome-related renal failure in 2 children. Age of patients at CLKT was 3 to 23 years (median 16 years) and body mass was 11 to 55 kg (median 35.5kg). All patients received whole liver graft. Kidney graft was transplanted after liver reperfusion before biliary anastomosis. Cold ischemia time was 5.5 to 13.3 hours (median 9.4 hours) for liver transplants and 7.3 to 15 hours (median 10.4 hours) for kidney transplants. In 8 patients X-match was positive. We analyzed posttransplant (Tx) course and late results in our group of pediatric recipients of combined grafts.

Results. Tx follow-up ranged from 1.5 to 17 years (median 4.5 years). Two patients died: 1 patient with oxalosis lost renal graft and died 2.6 years after Tx due to complications of long-term dialysis, and 1 died due to massive bleeding in early postoperative period. Twelve patients were transferred under the care of adult transplantation centers. Six patients were dialyzed after CLKT due to acute tubular necrosis, and time of kidney function recovery was 10 to 27 days in these patients. In 1 patient with aHUS, renal function did not recover. In children with oxalosis, hemodialysis was performed for 1 month after Tx as a standard, with the aim to remove accumulated oxalate. Primary immunosuppression consisted of daclizumab or basiliximab, tacrolimus, mycophenolate mofetil, and steroids. Acute rejection occurred in 4 liver and 3 kidney grafts. One patient required liver retransplantation due to hepatitis C virus recurrence and 2 patients required kidney retransplantation. Two patients required dialysis.

Conclusions. CLKT in children results in low rate of rejection and high rate of patient and graft survival.

COMBINED liver-kidney transplantation (CLKT) is a rare procedure in pediatric patients in which liver and kidney from 1 donor are transplanted to a single recipient during the same operation. The first simultaneous liver-kidney transplant was performed in 1983 by R. Margreiter (Innsbruck, Austria) [1]. It is routinely performed in many

Grant information: The creation of this study was supported by statutory grant from the Polish Ministry of Science and Higher Education award no. S153/2017.

*Address correspondence to Grzegorz Kowalewski, MD, Department of Pediatric Surgery and Organ Transplantation, Children's Memorial Health Institute, Aleja Dzieci Polskich 20, 04-730 Warsaw, Poland. E-mail: g.kowalewski@ipczd.pl

0041-1345/18
https://doi.org/10.1016/j.transproceed.2018.04.061

© 2018 Elsevier Inc. All rights reserved.
230 Park Avenue, New York, NY 10169

Table 1. Indications for CLKT in CMHI

Primary Diagnosis		No. of Patients		%
Fibro-polycystic liver and kidney disease	ARPKD	15	17	68
	ADPKD	2		
Primary hyperoxaluria type 1		6		24
Atypical HUS related renal failure		1		4
Atypical HUS related renal failure with liver cirrhosis due to HBV/HCV infection		1		4
Total		25		100

Abbreviations: ADPKD, autosomal dominant polycystic kidney disease; ARPKD, autosomal recessive polycystic kidney disease; HUS, hemolytic uremic syndrome; HBV, hepatitis B virus; HCV, hepatitis C virus.

transplant centers in patients with both liver and kidney failure.

CLKT was done for the first time in our center in 2000 as the first such transplantation in Poland.

The procedure was introduced in our center as result of extensive experience in kidney (since 1984) and liver (since 1990) transplantations. The few reports on CLKT in pediatric patients show encouraging results [2]. Possible limitations in children include body weight and patient size, although reports indicate that such transplants are feasible even in young children under 15 kg and in some cases even below 10 kg [3,4]. CLKT contains orthotopic transplantation of the whole, reduced, or split liver graft and kidney transplantation in the right or left iliac fossa of the recipient (less often intraperitoneally due to insufficient retroperitoneal space), from the same deceased donor. There are also isolated reports of liver and kidney transplantations from living related donors [5]. Indications leading to such transplantations are diseases resulting in irreversible liver and kidney failure: autosomal recessive polycystic kidney disease (ARPKD); end-stage renal disease (ESRD); hyperoxaluria type 1 (PH1); atypical hemolytic uremic syndrome (aHUS); metabolic and genetic liver disorders; severe liver disease; and end-stage kidney disease of different origins.

In PH1, liver-enzyme deficiency causes excessive calcium oxalate excretion and kidney deposition leading to ESRD. CLKT can correct this defect.

ARPKD is a rare but common cystic disease in children. The disease manifests itself in both kidney and liver damage leading, in varying degrees, to their failure. The most commonly described treatment and suggested first option is simultaneous renal and liver transplantation. Typical ESRD-induced hemolytic uremic syndrome (HUS) developing in children does not present risk of recurrence after isolated renal transplantation. In the case of children with aHUS, however, more than half of them develop ESRD with a high likelihood of recurrence after isolated renal transplant [6]. The aim of the study was to present long-term results of CLKT in children and analysis of accompanying problems after simultaneous kidney and liver transplantations.

Table 2. ABO Compatibility in CLKT Patients

ABO Compatibility	No. of Patients
Identical	19
Compatible but not identical	6
Total	25

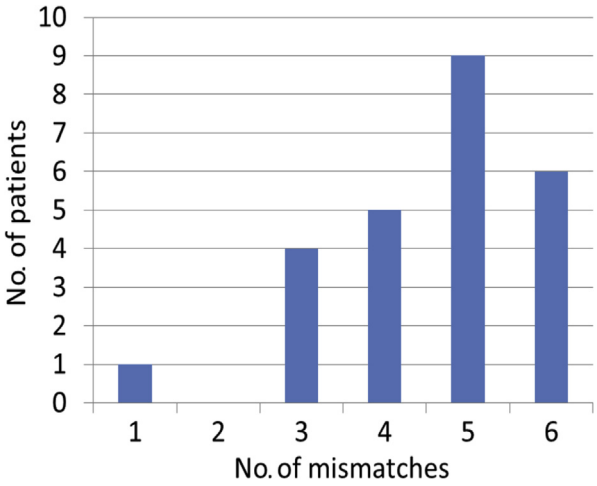

Fig 1. Distribution of HLA-A, HLA-B, and HLA-DR antigen mismatches of recipient/donor.

MATERIAL AND METHODS

Between 1984 and 2017, 920 kidney transplants (KT), including 119 from living donors, and 720 liver transplants (LT), including 333 from living donors, were performed; 25 combined liver-kidney transplants in 11 girls and 14 boys were performed.

Patients' age at CLKT ranged from 3 to 23 years (median 16 years). Recipients' body mass ranged from 11 to 55 kg (median 35.5 kg). Six (24%) patients were under the age of 10 years. The 23-year-old patient had a CLKT in our center because of the ongoing follow-up after previous KT as a pediatric patient and was therefore included in this analysis. Indications for CLKT were fibro-polycystic liver and kidney disease (FPLKD) in 17 patients, PH1 in 6 patients, and aHUS-related renal failure in 2 patients (1 patient with liver cirrhosis after HBV/HCV infection) (Table 1).

Transplant Surgery

Standards of transplant surgery included liver graft and kidney transplantation from the same donor. Anastomoses were performed in the following sequence: 1. liver vascular anastomoses and

Table 3. Primary Immunosuppression in CLKT Patients

Primary Immunosuppression	No. of Patients
daclizumab+tacrolimus+steroids	11
basiliximab+tacrolimus+MMF+steroids	7
daclizumab+tacrolimus+MMF	3
daclizumab+tacrolimus+MMF+steroids	3
tacrolimus+steroids	1
Total	25

Abbreviation: MMF, mycophenolate mofetil.

Download English Version:

https://daneshyari.com/en/article/8959190

Download Persian Version:

https://daneshyari.com/article/8959190

Daneshyari.com