




Contents lists available at ScienceDirect

Journal of Clinical Orthopaedics and Trauma

journal homepage: www.elsevier.com/locate/jcot

Application of three dimensional printing in surgery for cam type of femoro-acetabular impingement

Tarun Verma^{*},¹, Abhishek Mishra, Gaurang Agarwal, Lalit Maini

Maulana Azad Medical College and Lok Nayak Hospital, New Delhi, India

ARTICLE INFO

Article history:

Received 15 May 2018

Accepted 14 July 2018

Available online xxx

Keywords:

Femoroacetabular impingement

3D printed jigs

Virtual planning

Osteochondroplasty

Surgical dislocation

ABSTRACT

Surgical treatment of femoroacetabular impingement (FAI) focuses on improving the clearance for hip motion and alleviation of femoral abutment against the acetabular rim. Cam type of impingement is managed by performing an osteochondroplasty to remove the excess impinging bone from the head neck junction, thus improving the head neck offset. This procedure can be done by safe surgical dislocation, arthroscopy assisted mini-open method or all arthroscopy technique. Whatever be the approach, adequate excision of the Cam deformity is necessary to avoid suboptimal results. Under-excision leads to persistent symptoms and progression of disease, while over-excision can lead to weak bone vulnerable to fracture or disturb the labral seal. Various techniques utilized for intra-operative evaluation of amount of excision required described in literature are fluoroscopy, spherometer gauges, intra-operative Computed Tomography (CT) scan, navigation etc. Rapid prototyping, also called as three dimensional (3D) printing, is a technology to create dimensionally accurate model from a computer-assisted design. Accurate physical models can be designed from the medical imaging data like CT scans and 3D printed to aid in various medical applications. Its application in orthopaedic field is on a rise, recently. However, there is no report on utilization of this technique in surgeries for FAI. We have reported a case of Cam type FAI in an eighteen year old boy, which we treated surgically by performing osteochondroplasty using safe surgical dislocation. We did CT based virtual surgical planning to design femoral head and neck jigs, which were 3D printed and used intra-operatively to guide for adequate and optimum excision of bone at head neck junction. We found these customized jigs accurate and useful for the surgery. However, a comparison study with various other techniques is warranted for a detailed research on its usefulness and challenges. The main purpose of this article is to elaborate on the technical steps for designing of jigs for 3D printing to guide in osteochondroplasty surgery for FAI.

© 2018

1. Introduction

Femoroacetabular impingement is considered as a common cause of hip pain and secondary arthritis in young adults.¹ It is characterized by an abnormal patho-anatomy of the hip leading to abutment of the anterolateral head neck junction of femur against the anterolateral rim of acetabulum during the end range of motion.² This repeated pathologic contact eventually leads to the development of symptomatic FAI, a precursor to osteoarthritis.²

The two distinct forms described in literature are cam and pincer types. Surgical correction of patho-anatomy can halt the progression of the disease. Osteochondroplasty with open or arthroscopic approach is the mainstay surgery for cam type impingement. The goal of such surgeries is improving the clearance for hip motion and alleviation of femoral abutment against the acetabular rim by removing the aspherical portion of femoral head. Various techniques described in literature to assess the adequacy of osteochondroplasty are fluoroscopy, spherical gauges, computer-assisted surgery, intra-operative CT scan etc. Our report is the first ever description of cam type impingement surgically treated by using customized 3D printed jigs designed from CT scan through virtual planning.

^{*} Corresponding author. Present address: Room no 401, Old Resident Doctor's Hostel, Lok Nayak Hospital campus, New Delhi 110002, India.

E-mail addresses: tarunamiabledpv@gmail.com (T. Verma), mishra.abhishek85@gmail.com (A. Mishra), gaurang140389@gmail.com (G. Agarwal), lalit_maini@rediffmail.com (L. Maini).

¹ Permanent address: C-40, Omkar society, Maneja, Vadodara, Gujarat- 390013.

2. Case report

An eighteen year old boy presented with complaints of limp, pain and restricted movements of left hip, which gradually progressed over two years. He was unable to squat and do crossed leg sitting. He had a thirty degree of abduction deformity of left hip with restricted further abduction as well as internal rotation. There was an apparent lengthening of 3 cm on left side; however, true lengths of both lower limbs were equal.

Plain radiograph of pelvis with bilateral hip and CT scan with 1 mm sections were obtained [Fig. 1]. The imaging suggested Cam type of deformity on left side. We performed a virtual planning based on CT scan to design jigs for guiding in osteochondroplasty to decide on optimum excision.

Steps of the virtual planning and designing of the jigs are mentioned below.

- 1) CT scan was imported in Mimics Version 17.0 (Materialise NV, Belgium) software and thresholding was done to separate bone from soft tissue based on density. Segmentation and region growing steps were carried out to develop virtual 3D models of bilateral proximal femur bones [Fig. 2A and B]. The virtual proximal femoral 3D models were then transferred to 3-matic software (Version 9.0) as Stereolithography (STL) files. The models were then assessed. A sphere was designed on the right side (normal) femoral head matching its dimensions, hence called as fitting sphere [Fig. 2C]. The steps included marking of the femoral head surface using “brush mark” command and then selecting “fit sphere” method while designing the sphere based on the marked area. The diameter of the fitting sphere was measured and another sphere of 5 mm larger diameter was designed [Fig. 2D].
- 2) The second sphere was further hollowed using “hollow” command with 5 mm rim thickness. The hollowed sphere was then trimmed into a quarter of the sphere [Fig. 3A]. Further, a cylindrical attachment of 8 mm diameter and 3 cm length was designed and merged with this trimmed quarter-sphere to act

as a handle for holding during surgery. Another small cylindrical peg was designed and merged on anterior aspect of the jig for easy intra-operative identification of anterior and posterior side [Fig. 3B]. We named this jig as femoral head jig.

- 3) A bent plate (6 mm width and 3 mm thickness) matching the contour of neck at head neck junction on right side was designed [Fig. 3C]. A cylindrical attachment (8 mm diameter and 1.5 cm length) was designed and merged to this bent plate to act as a handle of this femoral neck jig [Fig. 3D].
- 4) The femoral head and neck jigs designed on the contra-lateral normal femur were then mirrored to left side using mid-plane as reference [Fig. 4]. The jigs were exported as STL files and converted into 3D printable G code in Slic3r software.
- 5) The jigs were printed in a 3D printer at 30% density using polylactic acid material and autoclaved before use in surgery [Fig. 5]. The total cost of 3D printed jigs was around 500 Indian Rupees (INR).

Informed consent for surgery was obtained from patient and his parents. Open osteochondroplasty was performed in lateral position using Ganz’s trochanteric flip approach with Z shaped anterior capsulotomy for safe surgical dislocation as described in literature. The femoral head was dislocated anteriorly. The femoral head cartilage was continuously irrigated with ringer lactate solution. The head and neck jigs helped us to guide the extent of resection at head-neck junction to obtain a spherical contour and appropriate head neck offset [Fig. 6]. Trochanteric flip osteotomy was fixed with two cancellous screws. Patient was kept on well leg traction for 3 weeks. Skate board exercises were initiated for range of motion. Patient was pain free with a fair range of motion on his last follow up one year after the surgery.

3. Discussion

FAI is a distinct pathologic entity that results from an abnormal morphologic relationship between the proximal femur and the acetabulum. Two distinct types of FAI have been identified- Cam

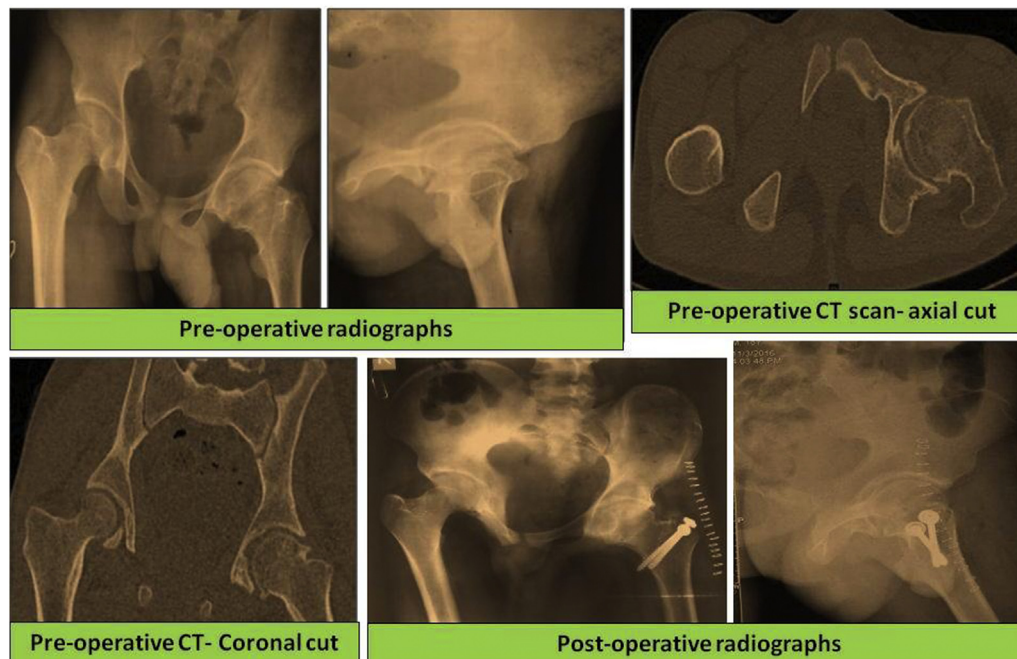


Fig. 1. Pre-operative plain radiographs, pre-operative CT sections and post-operative radiographs.

Download English Version:

<https://daneshyari.com/en/article/8963845>

Download Persian Version:

<https://daneshyari.com/article/8963845>

[Daneshyari.com](https://daneshyari.com)