

# Delayed Tension Pneumothorax During Surgery

Ying-Lun Chen\*, Chea-Ying Chen, Jen-Kun Cheng

*Department of Anesthesiology, Mackay Memorial Hospital, Taipei, Taiwan, R.O.C.*

Tension pneumothorax is a life-threatening emergency that rapidly results in cardiopulmonary arrest. It requires prompt diagnosis and treatment. We present 2 cases from our practice, 1 caused by blunt chest trauma and the other resulting from laparoscopic surgery. Both were successfully treated by insertion of a chest tube. The diagnosis and treatment of intraoperative pneumothorax is discussed together with a review of the literature. [*J Chin Med Assoc* 2005;68(10):491–494]

**Key Words:** barotrauma, cholecystectomy, laparoscopic surgery, pneumothorax

## Introduction

Tension pneumothorax occurs when intrapleural pressure exceeds atmospheric pressure. Expansion of the pneumothorax forces the lungs to collapse, resulting in increasing airway pressures. The increasing intrathoracic pressure exceeds venous and cardiac end-diastolic pressures, limiting cardiac filling, stroke volume, and blood pressure, the end result being pulseless electrical activity. Intraoperative tension pneumothorax may occur and must be promptly recognized and treated.<sup>1,2</sup> We report 2 cases of intraoperative tension pneumothorax.

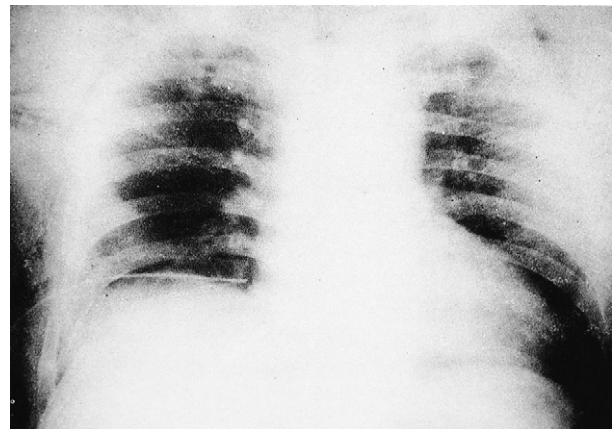
## Case Reports

### Case 1

A 40-year-old male, weighing 70 kg, was brought to the operating room for repair of a facial laceration after a traffic accident. A chest tube had been inserted in the emergency department for right hemopneumothorax. The patient's medical history was unremarkable. Physical examination revealed subcutaneous crepitus bilaterally over the anterior chest wall. The patient was mildly dyspneic. A chest X-ray revealed right sixth and seventh rib fractures, right hemopneumothorax with

a chest tube inserted, and bilateral subcutaneous emphysema (Figure 1).

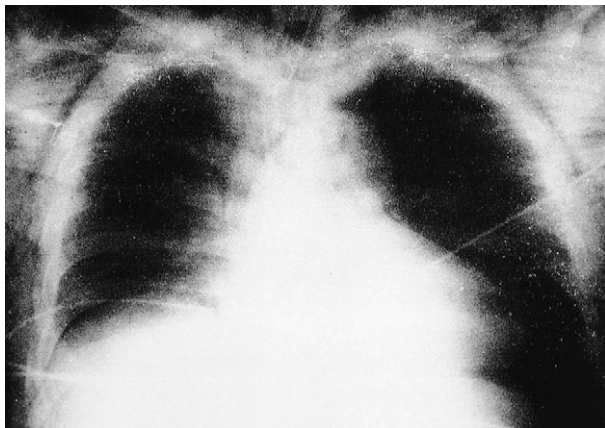
The initial vital signs were blood pressure (BP) of 120/60 mmHg, heart rate of 88 bpm, and oxygen saturation (SpO<sub>2</sub>) of 98%. Induction of general anesthesia and endotracheal intubation were uneventful. Peak inspiratory pressure (PIP), as displayed by the anesthesia machine, was 20 cmH<sub>2</sub>O. The end-tidal carbon dioxide (EtCO<sub>2</sub>) was maintained at about 35–40 mmHg.



**Figure 1.** Chest X-ray reveals right hemopneumothorax with a chest tube inserted.

\*Correspondence to: Dr. Ying-Lun Chen, Department of Anesthesiology, Mackay Memorial Hospital, 92, Section 2, Chungshan North Road, Taipei 104, Taiwan, R.O.C.

E-mail: alexingchaning@yahoo.com.hk • Received: October 15, 2004 • Accepted: May 25, 2005



**Figure 2.** Portable chest X-ray reveals left pneumothorax.

Approximately 1 hour into the operation, the BP decreased to 80/60 mmHg and the heart rate increased to 110 bpm. The SpO<sub>2</sub> decreased progressively from 99% to 90%. The PIP was 28 cmH<sub>2</sub>O and the EtCO<sub>2</sub> was 45 mmHg. Emergency chest X-ray revealed a left pneumothorax (Figure 2). A left chest tube was placed, the SpO<sub>2</sub> returned to 99%, and BP and heart rate became normal.

The operation was completed and the patient was transferred to the intensive care unit on mechanical ventilation. His postoperative course was uneventful, and he was extubated on the second postoperative day. He was discharged on the eighth postoperative day without sequelae.

### Case 2

A 71-year-old woman with gallstones was scheduled for laparoscopic cholecystectomy. She had a history of hypertension and congestive heart failure. Auscultation revealed bibasilar inspiratory crackles. A preoperative chest X-ray showed cardiomegaly and mild pulmonary congestion (Figure 3). An electrocardiogram showed atrial fibrillation with a ventricular rate of 130–140 bpm. The SpO<sub>2</sub> was 85–89% on room air.

After standard monitoring, anesthesia and relaxation were induced with etomidate 20 mg, fentanyl 100 µg, and atracurium 50 mg. Anesthesia was maintained with desflurane and 100% oxygen. Mechanical ventilation was initiated with a tidal volume of 0.5 L at a rate of 10 breaths/min. The EtCO<sub>2</sub> was 35–40 mmHg, the PIP was 26 cmH<sub>2</sub>O, and the SpO<sub>2</sub> increased to 99%.

A pneumoperitoneum was instituted, after which the PIP increased to 33 cmH<sub>2</sub>O. The laparoscopic surgery continued for about 10 minutes but was converted to an open procedure because of technical difficulty. The PIP then decreased to 28 cmH<sub>2</sub>O. One

hour later, the operation was completed, and the patient resumed spontaneous respiration. Her SpO<sub>2</sub> at that point was 98%.

In the postanesthesia room, she remained intubated on a T-piece with 100% oxygen. Her BP was 150/115 mmHg, heart rate was 100 bpm, and SpO<sub>2</sub> was 95%. Ten minutes later, she was noted to have labored breathing. The SpO<sub>2</sub> decreased to 87%, BP dropped to 75/45 mmHg, and the heart rate increased to 130 bpm. Her abdomen was distended. Internal bleeding was suspected, so she was sent back to the operating room, where she soon became severely cyanotic. Her heart rate was 170 bpm and the BP could not be measured. The EtCO<sub>2</sub> decreased to 6–8 mmHg and the PIP was 50–60 cmH<sub>2</sub>O. Breath sounds were absent on the left and a left tension pneumothorax was suspected. A 16-gauge needle was inserted into the left chest, resulting in a rush of air and immediate improvement in the BP and SpO<sub>2</sub>. The PIP decreased to 28 cmH<sub>2</sub>O and the EtCO<sub>2</sub> increased to 40 mmHg. The abdominal distension also resolved. A left chest tube was then placed. Chest X-ray showed re-expansion of the left lung (Figure 4). The patient's subsequent course was unremarkable, and she had no neurologic damage. The endotracheal tube was removed on the fourth postoperative day. She was eventually discharged without sequelae.

### Discussion

Pneumothorax occurring during general anesthesia is a rare event, accounting for less than 3% of anesthesia complications.<sup>3</sup> The most common causes are regional blocks (40% of reported cases), airway instrumentation (19%), barotrauma (16%), and placement of central venous lines (7%).<sup>4</sup> Patients with chronic obstructive pulmonary disease are at increased risk.<sup>5</sup>

Our first patient had rib fractures on the right but not on the left. The initial PIP was not elevated, nor was there any sign of a left pneumothorax on the preoperative chest X-ray. We postulate that the pneumothorax was caused by a previously unrecognized visceral pleural laceration related to the original trauma but which was asymptomatic when the patient was breathing on his own. Positive pressure mechanical ventilation, however, could have caused an air leak from the laceration, resulting in the tension pneumothorax.

Signs of a pneumothorax may be masked during anesthesia. The presenting feature in this case was intraoperative hemodynamic instability. Tachycardia

Download English Version:

<https://daneshyari.com/en/article/9296324>

Download Persian Version:

<https://daneshyari.com/article/9296324>

[Daneshyari.com](https://daneshyari.com)