

*Original article*

## Importance of the lateral anatomic tibial slope as a guide to the tibial cut in total knee arthroplasty in Japanese patients

TAKASHI KUWANO<sup>1</sup>, KEN URABE<sup>2</sup>, HIROMASA MIURA<sup>1</sup>, RYUJI NAGAMINE<sup>1</sup>, SHUICHI MATSUDA<sup>1</sup>,  
MASATOSHI SATOMURA<sup>1</sup>, TOSHIAKI SASAKI<sup>1</sup>, SHUJI SAKAI<sup>3</sup>, HIROSHI HONDA<sup>3</sup>, and YUKIHIRO IWAMOTO<sup>1</sup>

<sup>1</sup>Department of Orthopaedic Surgery, Graduate School of Medical Sciences, Kyushu University, Fukuoka, Japan

<sup>2</sup>Department of Orthopaedic Surgery, Kitasato University School of Medicine, 1-15-1 Kitasato, Sagami-hara, 228-8555, Japan

<sup>3</sup>Department of Clinical Radiology, Kyushu University, Fukuoka, Japan

**Abstract** Using three-dimensional computed tomography in 50 osteoarthritic knees, we simulated at various cutting angles the tibial cut for total knee arthroplasty. Cutting angles of 0°, 3°, 5°, 7°, 9°, and 11° were used. We then calculated the anterior and posterior thicknesses, the medial-lateral widths, and the medial and lateral condylar depths of the resected tibial bone at each cutting angle. Each set of measurements was evaluated according to a comparison between the cutting angle and the anatomic posterior slopes. The cutting angles showing the smallest anterior-posterior difference at the medial and lateral plateaus were 9° and 7°, respectively. The mean anatomic posterior slopes at the medial and lateral plateaus were 9.0° and 8.1°, respectively. When the tibia was cut at the cutting angle closest to the medial anatomical posterior slope in each knee, the thickness of the lateral posterior plateau resected from 12 knees (24%) was more than 10mm. Among these 12 knees, the cutting angle was more than 9° in 9 knees (75%). In contrast, when the tibia was cut at the cutting angle closest to the lateral anatomical posterior slope, only one resected medial posterior plateau was more than 10mm. The cutting angle of this case was 7°. Therefore, in consideration of the thickness of bone resection from anatomic posterior slope, we demonstrated the importance of using the lateral anatomic posterior tibial slope as a guide to the tibial cut. There was no significant difference with respect to resected bone morphology at any cutting angle.

**Key words** Total knee arthroplasty · Posterior tibial slope · Computed tomography · Osteoarthritis

### Introduction

It is important to restore proper alignment when performing total knee arthroplasty (TKA). The posterior tibial slope after TKA affects anteroposterior stability, range of motion, and contact pressure within the femorotibial joint. An inappropriate cutting angle of the pos-

terior tibial slope results in polyethylene wear, component loosening, and posterior cruciate ligament (PCL) strain.<sup>4,8,11</sup> Some total knee systems have been designed to cut the proximal tibia with a specific posterior slope, whereas others have been designed to cut the tibia perpendicular to the longitudinal axis of the tibial shaft.<sup>6</sup> The proper cutting angle for the posterior tibial slope is still controversial. Changes in the posterior tibial slope after TKA affect the strain on the PCL and other posterior stabilizers of the joint. For surgeons who correct the soft tissue balance before the initial bone cut, it is important that the tibial cut in the sagittal plane does not alter this balance. For surgeons who cut the bone first, it is important to note that excessive anteroposterior instability cannot be repaired by soft tissue release. Thus, to minimize the effect of the sagittal plane tibial cut on the soft tissue balance, it is desirable to minimize any alteration to the posterior tibial slope with surgery, as reflected by the extent to which differences in the thickness of the anterior and posterior portion of the resected tibia is minimized.

In this study, we evaluated the effect of the posterior tibial slope on the thickness of the resected bone and the morphology of the resected surface, which we simulated at various cutting angles of the posterior slope using three-dimensional computed tomography (3D CT). The aim of this study was to identify a reliable landmark to minimize differences in thickness between the anterior and posterior portions of resected tibia and to investigate the influence of the cutting angle of the posterior slope on the morphology of the resected surface.

### Materials and methods

#### Subjects

We studied 50 osteoarthritic knees in 32 patients. The mean age of the patients was 71.4 years (range 58–81

years). The population consisted of 5 knees in 3 males and 45 knees in 29 females. All patients had medial-type osteoarthritis. The mean femorotibial angle on the standing anteroposterior (AP) radiograph was  $185.3^\circ$  (range  $180^\circ$ – $189^\circ$ ; SD  $2.7^\circ$ ). According to the Kellgren and Lawrence classification, all knees had radiographic evidence of grade 4 osteoarthritis.

Following this study, all knees underwent high tibial osteotomy or TKA using standard procedures uninfluenced by the computerized simulation. All subjects gave informed consent for participation in this study.

### Computed tomographic technique

The patients were placed supine in the scanner with their knees taped to the scanner platform in the extended position. The patellae were facing directly anteriorly. Rapid 2-mm helical CT scans at 2.5 pitch were performed using an X Vigor Real (Toshiba Medical System, Tokyo, Japan) (table speed 5 mm/s; 120 kVp; 50 mA; 512 matrix; body FOV 240 mm). The scan length was 300 mm (150 mm above and 150 mm below the joint line of the knee). A total of 121 images were retrospectively reconstructed at 2.5-mm intervals with  $180^\circ$  interpolation and then reformatted with 3D reconstruction (Xtension Version 2; Toshiba Medical System) to produce 3D CT images of the tibia and the distal femur. 3D CT images were reconstructed by a surface rendering technique. The threshold is 234 Hounsfield units. Once the data are acquired, the software can be used to rotate, clip, and measure the image.

### Decision regarding tibia position

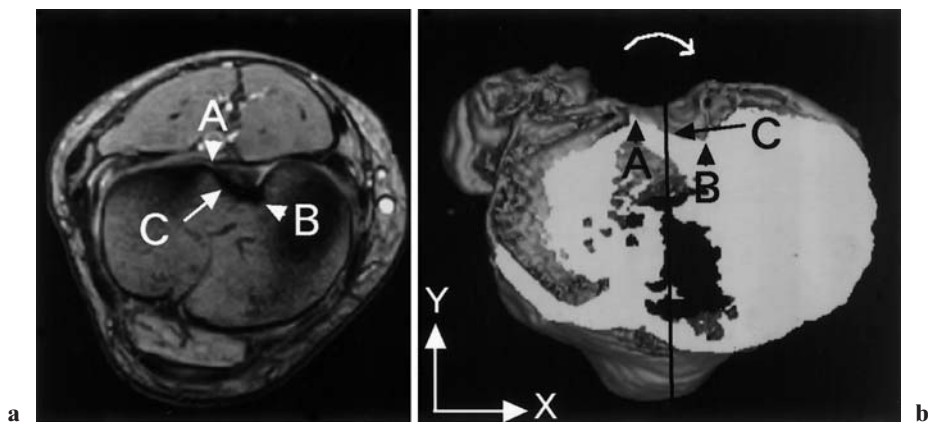
Initially, we evaluated the position of the PCL attachment 10 mm below the lateral tibial articular surface on the horizontal plane by magnetic resonance imaging (MRI) in five cases. We found that the center of the PCL attachment (point C) was the midpoint between the most posterolateral aspect (point A) and the most anterior aspect (point B) of the posterior intercondylar area in some cases (Fig. 1a). The 3D CT image, which was sliced at the same level as the MRI, was subsequently evaluated. We morphologically confirmed the most posterolateral aspect as point A and the most anterior aspect as point B in the 3D CT image. Therefore, this midpoint (point C) was defined as the center of the PCL attachment on 3D CT images. Also in the horizontal plane in 3D CT image, the anteroposterior axis of the tibia was defined as a line drawn from the one-third medial side of the tibial tubercle to the center of the PCL attachment (point C). Using these references, the tibia was rotated to align the anteroposterior axis parallel to the Y axis on the horizontal plane (Fig. 1b).

Finally, the longitudinal axis of the tibial shaft, defined as the anatomical axis of the tibial shaft on the 3D image, was aligned parallel to the Y axis on both the anteroposterior and the lateral views (Fig. 2).

### Measurements

#### Anatomic posterior tibial slope

To determine the posterior slope of the medial and lateral plateau, the anterior and posterior corner of



**Fig. 1.** **a** Magnetic resonance (MR) image of the horizontal plane of the articular surface of the proximal tibia. Points A and B show the most posterolateral and the most anterior aspects of the posterior intercondylar area. Point C indicates the midpoint of points A and B and is the midpoint of the posterior cruciate ligament (PCL) attachment. **b** Each point in

this three-dimensional (3D) image corresponds with each point in the MR image. Determination of the anteroposterior axis of the 3D computed tomography (CT) image in the horizontal plane. A line was drawn connecting the one-third medial side of the tibial tubercle and point C

Download English Version:

<https://daneshyari.com/en/article/9354938>

Download Persian Version:

<https://daneshyari.com/article/9354938>

[Daneshyari.com](https://daneshyari.com)