Forensic Science International 255 (2015) 106–111

Contents lists available at ScienceDirect

Forensic Science International

journal homepage: www.elsevier.com/locate/forsciint

Use of 3D reconstruction of emergency and postoperative craniocerebral CT images to explore craniocerebral trauma mechanism

Zhengdong Li [1], Donghua Zou [1], Jianhua Zhang, Yu Shao, Ping Huang [1,*], Yijiu Chen [1,*]

Shanghai Key Laboratory of Forensic Medicine, Institute of Forensic Science, Ministry of Justice, 1347# West Guangfu Road, Shanghai 200063, China

ARTICLE INFO

Article history:
Available online 17 July 2015

Keywords:
Assembled 3D reconstruction
Virtopsy
Craniocerebral trauma
Injury mechanism

ABSTRACT

We report a craniocerebral trauma case in which a man sustained severe skull fractures and cerebral contusions and it demanded elucidating the injury mechanism of being formed by strike or tumble. However, the initial features of skull fractures were mostly lost when the forensic pathologists involved in the case 5 months later because of injury healing and craniocerebral surgery. Therefore, we aimed to reconstruct the original skull fracture features by utilizing the digital reconstruction technologies in terms of CT (computed tomography) scanning, 3D (3-dimentional) reconstruction, and virtual surgical tools. The original fracture skull was assembled by using Mimics 13.0 based on the CT slices of postoperative head and the removed craniotomy skull flaps, which revealed fracture features of focal and overall skull deformation. Based on the assembly skull model and the contrecoup cerebral contusions, we conclude that the man suffered a tumble after being drunk and the serious craniocerebral trauma occurred. The case demonstrated that the digital reconstruction technologies can serve as effective approaches for forensic investigation in case of survived craniocerebral trauma patients without direct evidences interpreting the original trauma patterns, which could potentially be helpful in exploring the injury mechanisms.

1. Introduction

Medical imaging technologies have been an important and commonly used tool in forensic science [1–6], as it is nondestructive, visualizing, and documenting complete information [1]. In forensic autopsy practices, the forensic pathologist always needs to assess the injury locations, degrees and morphologies of soft tissues, bones and intracorporeal organs, to analyze the cause of death and injury mechanisms. Craniocerebral trauma is a common cause of fatality and disability. The head trauma mechanisms are always complex for forensic pathologists to analyze, especially when there were insufficient initial trauma features since the experts were involved in up to days or months later and the emergency treatments would change the trauma features. Generally, the forensic experts will identify the injury mechanism by imaging diagnosis and 3D model resulted from the initial medical images. However, the clinicians are primarily focused on the trauma, therapeutic and prognostic implications, which lead to lack of detailed injury descriptions and sometimes the initial image thickness is not precise enough to reconstruct the original trauma [6]. Furthermore, craniocerebral trauma was the worst prognosis or even life-threatening, hence emergency surgery is needed to be operated to save the patient immediately, which will change the original trauma characteristics. As some of the initial trauma features are lost, especially for the skull fractures, there is no direct way to reconstruct the trauma features and it is necessary to assemble different kind of separate model into an integral model to show the original trauma [7–9].

Mimics (Materialise Inc., Belgium) is a specialized medical image processing software, which could easily and quickly create accurate 3D models from the medical image data. The virtual surgical tools of Mimics can simulate osteotomies by cutting bone, repositioning parts as well as placing implants and bone plates to select the optimal surgery plan [10,11]. In this case, the tools are available for reassembling the surgical removed skull flaps with residual skull together in the absence of the original fracture features. This is the first case in which the 3D reconstruction and virtual surgical tools were applied to restore the original skull fracture in forensic practice, proved to be an effective complementary approach in the craniocerebral trauma mechanism without initial fracture patterns on account of the head surgical operations based on the clinical images.

* Corresponding authors.
E-mail addresses: huangpingifs@gmail.com (P. Huang), yijiuchen@gmail.com (Y. Chen).
[1] These authors contributed equally to this work.

http://dx.doi.org/10.1016/j.forsciint.2015.07.012
0379-0738/

2. Case report

2.1. Case information

In this case, an adult man aged 40 years old was drunk and made trouble in his friend's house. Then he got arrested into the police station at 22:00 and 5 minutes later the man fainted, and was sent to the hospital for rescue immediately. He was taken to the local hospital first where an emergency head CT scan was performed at 22:16 with severe craniocerebral traumas. After six hours the man was transferred to the provincial neurological hospital for mega-bone flap craniotomy decompression operation. Up until forensic pathologists involved in the case 5 months later, the man had never regained consciousness. The local police entrusted this case to our forensic pathologists to find out whether the head traumas were caused by tumble or strike, and the surveillance videos, scene photos, emergency head CT slices, postoperative craniocerebral CT DICOM (Digital Imaging and Communications in Medicine) dataset, postoperative scalp photos, and postoperative skull bone flaps were collected as the investigation and identification basis data.

2.2. Medico-legal investigations

2.2.1. Retrospective Analysis of Clinical Data

CT analysis for clinical radiological diagnostics and forensic radiological reading were carried out by experienced certified radiologists and forensic pathologists. The emergency CT film performed by the first local hospital at 22:16 indicated that scalp swelling in the right temporal–parietal part, depression fracture on the right parietal–occipital bones, subdural hematoma in the right temporal–parietal part, subarachnoid hemorrhage, cerebral contusions in the left frontal lobe, and compression of the right lateral ventricle (Fig. 1). With the empirical inference, the contrecoup brain contusions showed the deceleration injuries mechanism, while the depression fracture of the skull is already too complex to explain the injury process. Hence, more exploration was to be carried out. The initial emergency CT film was scanned and divided into 12 slices to reconstruct the original rough 3D model of the skull fractures. There was another postoperative craniocerebral CT DICOM data with 0.6 mm slice thickness performed by the second provincial neurological hospital 41 days after the trauma. It indicated that the fractured skull was removed and a mega bone window was formed in the right temporal–parietal–occipital skull, the scalp swelling was decreased, the subdural hematoma disappeared and the right frontal and temporal lobes had the pathological changes of brain contusions.

A total of four postoperative scalp photos taken by the police, 40 days after the patients injury were carefully inspected by our forensic pathologists to verify probable fractures and wound scars. The photos clearly revealed a series of healed U shaped linear and curved incision scars in the right frontal, parietal, and occipital part of the head. No obvious scalp abrasions, contusions, and lacerations were observed. There were also healed surgical incision scars in the left temporal part of the scalp.

2.2.2. Examination of the Skull Flaps

Postoperative skull bone flaps were carefully inspected by our forensic pathologists to verify skull fractures. The removed fragmentary flaps from the victim's head were closely examined and assembled into one integral bone flap. In consideration of vital reaction (skull cancellous bone hemorrhage) and the wedge-shaped fractures on the margin of fragmentary flaps, four fracture lines were identified and verified (Fig. 2). These lines went from posterior to anterior and from superior to inferior, with an arc-like fracture and some irregular lines placed on the flap. However, taking into account these materials we could not imply anything about the injury mechanisms.

CT examination of the integrated skull flap was performed on a 40-row CT scanner (Siemens Medical Solutions, Germany) in our

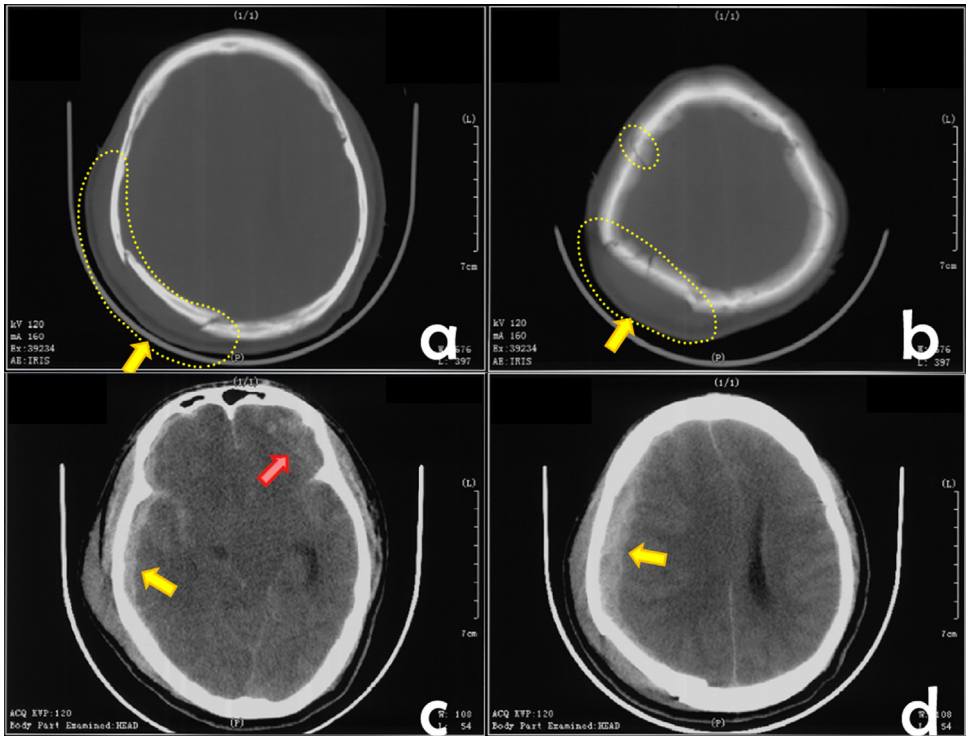

Fig. 1. Emergency CT slices of the traumatic head. a and b: Scalp swelling and depression fracture on the right parietal–occipital part. (Yellow arrow: scalp swelling; Yellow dotted circle: skull depression fractures); c and d: subdural hematoma, subarachnoid hemorrhage and cerebral contusions. (Red arrow: cerebral contusions; Yellow arrow: subdural hematoma).