




ELSEVIER

Contents lists available at ScienceDirect

## Interdisciplinary Neurosurgery

journal homepage: [www.elsevier.com/locate/inat](http://www.elsevier.com/locate/inat)

## Case Reports &amp; Case Series

## Spontaneous intracranial hypotension complicated by refractory subdural hematomas in a patient with coagulation factor XIII deficiency

Ronit Gilad<sup>a,\*</sup>, Soriaya L. Motivala<sup>a,1</sup>, Sharukh Khan<sup>a,1</sup>, Edwin Chang<sup>a,1</sup>, Daniel L. Klein<sup>b,2</sup>, Mark J. Raden<sup>b,2</sup><sup>a</sup> Department of Neurosurgery, Staten Island University Hospital, Staten Island, NY, United States<sup>b</sup> Department of Radiology, Staten Island University Hospital, Staten Island, NY, United States

## ARTICLE INFO

## Keywords:

Spontaneous intracranial hypotension  
Subdural hematoma  
Epidural blood patch  
Coagulation factor XIII deficiency

## ABSTRACT

Spontaneous intracranial hypotension (SIH) is often secondary to an occult cerebrospinal fluid (CSF) leak in the neuroaxis. It is sometimes associated with chronic subdural hematomas (SDH). The authors present the case of a 61 year-old male who presented with SIH from an occult CSF leak and complicated by refractory SDH. The patient underwent treatment for SIH with multiple epidural blood patches, hydration and bed rest. In addition, he underwent evacuation of his SDH twice, once via burr hole drainage and the second via craniotomy. Once the diagnosis of coagulation factor XIII (CFXIII) deficiency was made, the patient was treated with recombinant factor XIII followed by an epidural blood patch. He subsequently made a complete recovery. In this report, the authors propose management strategies for treating patients with SIH complicated by refractory SDH and coagulopathies by reviewing the literature.

## 1. Introduction

Spontaneous intracranial hypotension (SIH) is often secondary to an occult cerebrospinal fluid (CSF) leak in the neuroaxis. It is sometimes associated with chronic subdural hematomas (SDH). The combination of clinical symptoms and neuroimaging should alert the practitioner of SIH and therefore guide the practitioner to the appropriate treatment [4,6]. The treatment of choice in this situation is an epidural blood patch if conservative measures such as bedrest and hydration fail. For larger SDH, evacuation may be necessary in conjunction with an epidural blood patch. However, refractory subdural hematomas may complicate the situation despite appropriate management [7]. Coagulation factor XIII (CFXIII) is a clot stabilizing factor in the clotting cascade and has also been shown to contribute to wound healing by encouraging the migration and proliferation of fibroblasts into the clot [1,5]. We present a case of a healthy 61 year-old male who presented with SIH from an occult CSF leak and complicated by refractory SDH. He did not respond to treatment until the diagnosis of CFXIII was made and treated appropriately.

## 2. Case presentation

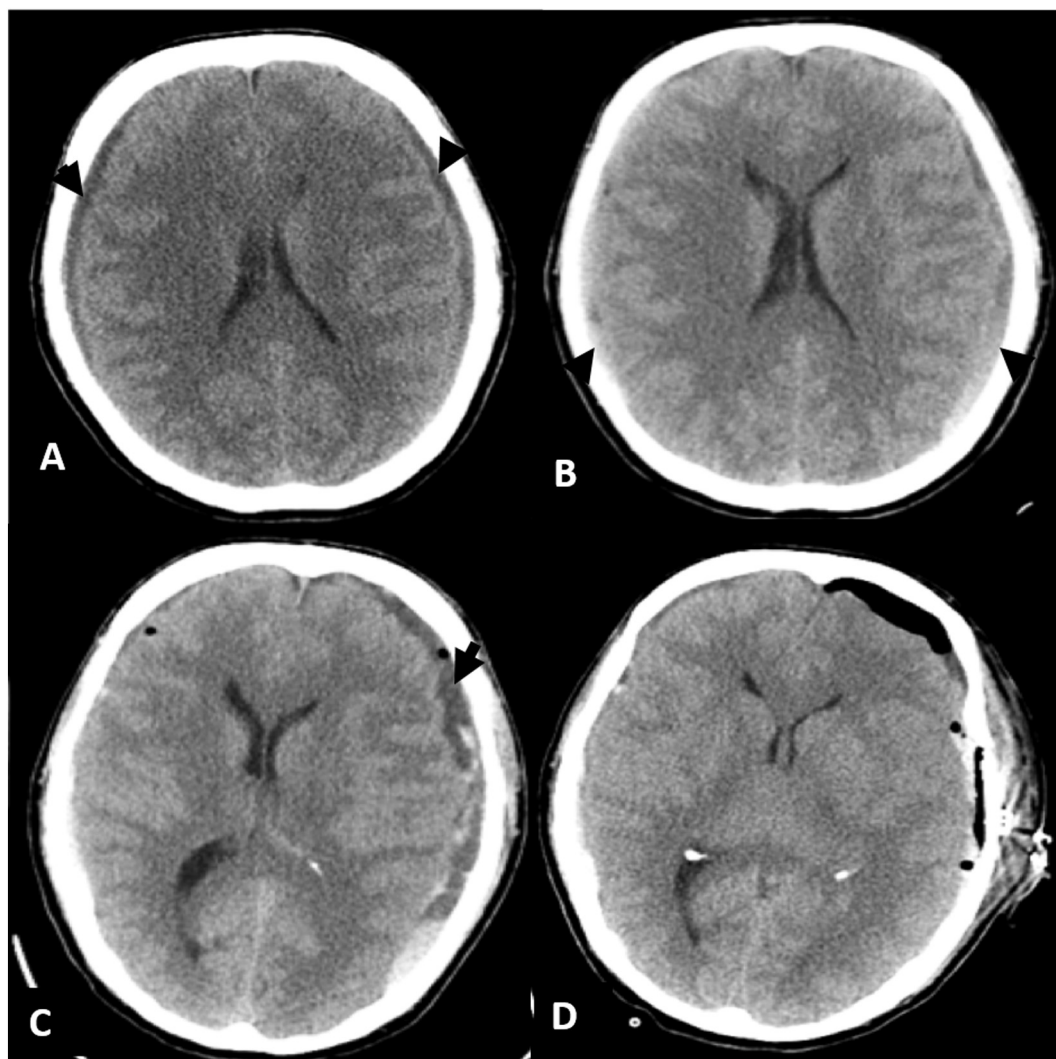
A 61 year-old right handed male with no past medical history presented to our emergency department with 3 days of progressively worsening headaches. The headaches were severe and positional in nature. He had a nonfocal neurologic examination. A noncontrast computed tomography (CT) of the head showed bilateral hypodense subdural collections (Fig. 1A). At this point, spontaneous intracranial hypotension (SIH) as a result of occult cerebrospinal fluid leak (CSF leak) was suspected based on clinical and radiological exam.

As part of his work-up for an occult CSF leak magnetic resonance imaging (MRI) of the neuroaxis (brain, cervical, thoracic and lumbar spine) was obtained which demonstrated several small nerve root sleeve cysts in the midthoracic region. A CT myelogram was subsequently obtained with no further findings. Since no obvious source of leak was found, the decision was made to manage him conservatively with bed rest, intravenous fluids, and caffeine pills. His headaches improved substantially after 2 days and he was discharged home after a CT demonstrated stability of his subdural collections.

He returned one week later with severe positional headaches. A follow-up CT scan demonstrated an increase in the size of the subdural

\* Corresponding author at: 501 Seaview Ave Suite 104, Staten Island, NY 10305, United States.

E-mail addresses: [rgilad@northwell.edu](mailto:rgilad@northwell.edu) (R. Gilad), [smotivala@northwell.edu](mailto:smotivala@northwell.edu) (S.L. Motivala), [echang2@northwell.edu](mailto:echang2@northwell.edu) (E. Chang), [dklein@northwell.edu](mailto:dklein@northwell.edu) (D.L. Klein), [mraden@northwell.edu](mailto:mraden@northwell.edu) (M.J. Raden).<sup>1</sup> 501 Seaview Ave Suite 104, Staten Island, NY 10305, United States.<sup>2</sup> 475 Seaview Ave, Staten Island, NY 10305, United States.



**Fig. 1.** Axial CT of the head on presentation (A), 7 days after presentation (B), 4 days after bilateral burr hole drainage (C), and post-craniotomy (D) demonstrating the subdural hematomas.

collections with additional acute blood (Fig. 1B). Although nonfocal on his initial neurologic exam, he became lethargic despite intravenous fluids and lying flat for 24 h. The decision was then made to take him to the operating room and drain the subdural hematomas with bilateral burr holes. On postoperative day one his symptoms improved and a postoperative CT demonstrated significant reduction in the subdural fluid collections. However, by the second postoperative day, his symptoms of severe positional headaches and lethargy recurred. At this point, a blood patch was performed using 60 ml of autologous blood injected through a spinal needle into the epidural space of the lumbar spine.

The patient's headaches did not improve after the blood patch. In addition, he developed word finding difficulties. Due to the new focal neurologic deficit, a CT scan was performed which showed an increase in size of the left subdural collection with associated mass effect and acute blood (Fig. 1C). Due to the reappearance of acute blood in the subdural collection, a hematology consult was obtained. He was taken to the operating room for a left sided craniotomy and evacuation of the subdural hematoma. A postoperative CT demonstrated evacuation of the hematoma (Fig. 1D) and a second blood patch was performed. The patient initially improved.

By postoperative day 2, despite being kept flat, he became progressively obtunded and required intubation. An MRI of the brain demonstrated downward displacement of the cerebellar tonsils and

splenium of the corpus callosum with severe crowding of the foramen magnum. Progressive sulcal, third and fourth ventricle, and basal cistern effacement was seen consistent with severe intracranial hypotension. The patient was placed in 30 degrees Trendelenberg and within 15 min he regained consciousness. At this time, his hematology work-up revealed a severe coagulation factor XIII deficiency, at a level of 23% in his plasma (normal range, 70–140%). The patient was given recombinant factor XIII intravenously followed by a third blood patch. He subsequently made a complete recovery. A surveillance CT scan was performed as an outpatient and demonstrated complete resolution of the subdural collections.

### 3. Discussion

Spontaneous intracranial hypotension (SIH) should be suspected in patients with postural headaches. In patients with SDH who have postural headaches and no history of trauma or coagulopathy, the diagnosis and treatment of SIH is critical for a favorable outcome. Recurrence of SDH associated with SIH is common until treatment of the underlying CSF leak is achieved [3,7]. There is ample evidence that epidural blood patch (EBP) alone is effective in treating patients with chronic SDH associated SIH even when the site of CSF leak has not been identified [3]. Repeated EBP may be required in patients. In the rare refractory patient, surgical repair of a CSF leak is required but is

Download English Version:

<https://daneshyari.com/en/article/9989504>

Download Persian Version:

<https://daneshyari.com/article/9989504>

[Daneshyari.com](https://daneshyari.com)