

## ORIGINAL ARTICLE

# Photodynamic therapy is associated with an improvement in survival in patients with irresectable hilar cholangiocarcinoma

Aaron J. Quyn, Dorin Ziyaie, Francesco M. Polignano & Iain S. Tait

Department of Surgery & Molecular Oncology, Ninewells Hospital & Medical School, Dundee, Scotland, UK

## Abstract

**Background:** The majority of patients with hilar cholangiocarcinoma have irresectable disease and require palliation with biliary stenting to alleviate symptoms and prevent biliary sepsis. Chemotherapy and radiotherapy have proved ineffective, but recent studies suggest photodynamic therapy (PDT) may improve the outlook for these patients. This prospective clinical cohort study has evaluated the efficacy of radical curative surgery, standard palliative therapy (stent  $\pm$  chemotherapy) and a novel palliative therapy (stent  $\pm$  Photofrin-PDT) in 50 consecutive patients treated for hilar cholangiocarcinoma over a 5-year period.

**Methods:** Between January 2002 and December 2006, 50 patients with hilar cholangiocarcinoma were evaluated for treatment. Ten patients were considered suitable for curative resection (Cohort 1). Forty patients with irresectable disease were stratified into Cohort 2 – Stent  $\pm$  chemotherapy ( $n = 17$ ); and Cohort 3 – Stent  $\pm$  PDT ( $n = 23$ ). Prospective follow-up in all patients and data collected for morbidity, mortality and overall patient survival.

**Results:** The median age was 68 years [range 44–83]. Positive cytology/histology was obtained in 28/50 (56%). One death in Cohort 1 occurred at 145 days after surgical resection. No treatment related-deaths occurred in Cohort 2 or 3, chemotherapy-induced morbidity in three patients in cohort 2, PDT-induced morbidity in 11 patients in cohort 3. Actual 1-year survival was 80%, 12% and 75% in Cohorts 1, 2 and 3, respectively. Mean survival after resection was 1278 days (median survival not reached). Mean and median survival was 173 and 169 days, respectively, in Cohort 2; and 512 and 425 days in Cohort 3. Patient survival was significantly longer in cohorts 1 and 3 ( $P < 0.0001$ ; Log rank test).

**Conclusion:** This prospective clinical cohort study has demonstrated that radical surgery and palliative Photofrin-PDT are associated with an increased survival in patients with hilar cholangiocarcinoma.

## Keywords

hilar cholangiocarcinoma, survival, curative surgery, photodynamic therapy

Received 24 February 2009; accepted 23 May 2009

## Correspondence

Iain S. Tait, Department of Surgery & Molecular Oncology, Ninewells Hospital & Medical School, Dundee DD1 9SY, UK. Tel: +44 (0) 1382 632174; Fax: +44 (0) 1382 496361; E-mail: i.z.tait@dundee.ac.uk

## Introduction

Hilar cholangiocarcinoma was first described by Altemeir *et al.* in 1957,<sup>1</sup> but it was only after Klatzkin described a series of 13 patients in 1965 that this tumour was recognized as a distinct clinical entity.<sup>2</sup> These uncommon tumours have an incidence of 1.2 per 100,000 in the western population<sup>3,4</sup> and account for 60–70% of all primary bile duct cancers.<sup>4–6</sup> Hilar cholangiocarcinoma has an extremely poor prognosis with less than 5% of patients surviving 5 years.<sup>7</sup>

Surgical resection offers the only curative option and usually requires a major hepatic resection in addition to resection of the actual bile duct cancer.<sup>8</sup> Unfortunately, curative resection is only possible in 20% of patients because of locally advanced disease, distant metastases or co-morbidity in an elderly population.<sup>9</sup>

Therefore, effective palliation to relieve the symptoms associated with jaundice and the prevention of biliary tract infection are the fundamental goals for most patients with hilar cholangiocarcinoma. Relief of biliary tract obstruction by

endoscopic or percutaneous placement of plastic or metal stents is regarded the optimal first-line palliation as this achieves similar survival (6.8 months vs. 5.4 months) to surgical bypass, but with less procedure-related morbidity (17–51%) or mortality (6–12%) and at substantially lower cost.<sup>8–11</sup>

However, even after successful stent insertion the clinical course is one of disease progression and death from liver failure or cholangitis within 4–9 months.<sup>7,12–14</sup> Many studies have evaluated chemotherapy, external beam radiotherapy and brachytherapy but have not demonstrated a meaningful survival benefit in this patient population.<sup>15–18</sup>

As a result, novel therapies such as photodynamic therapy (PDT) are being evaluated for treatment of cancers that have proved resistant to standard oncological treatment. PDT destroys cancerous tissue by stimulating a photochemical reaction within the lesion using the combination of a photosensitizing drug and a specific wavelength of light.<sup>19</sup> The photosensitizer drug is activated by intense illumination with (laser) light to generate highly reactive oxygen species that result in cellular injury. This photodynamic reaction destroys cancerous tissue by direct cytotoxicity, microvascular damage,<sup>20</sup> cytosolic and mitochondrial membrane damage; and release of inflammatory mediators that induce a T-lymphocyte-mediated cellular immune response.<sup>21–23</sup>

Preliminary clinical studies have suggested that PDT may be beneficial for palliation of hilar cholangiocarcinoma<sup>24–28</sup> and a recent study demonstrated a substantial survival benefit for PDT in jaundiced patients with advanced cholangiocarcinoma.<sup>29</sup> The aim of this prospective clinical cohort study was to evaluate the efficacy of radical curative surgery, standard palliative therapy (stent  $\pm$  chemotherapy) and a novel palliative therapy (stent  $\pm$  Photofrin-PDT) in the management of patients with hilar cholangiocarcinoma.

## Patients and methods

### Patients

Fifty-four patients with hilar cholangiocarcinoma were assessed at the Hepatobiliary unit at Ninewells Hospital & Medical School between January 2002 and December 2006, and 50 patients suitable for active treatment were included in the study. This single centre study included 10 patients referred for PDT from other Scottish hospitals. Patients aged at least 18 years with a hilar cholangiocarcinoma (Bismuth types II–IV) were considered for inclusion in the study, and the use of Photofrin-PDT for bile duct cancer was approved by the Tayside Regional Ethics committee. Four frail patients with extensive metastatic disease were considered too unfit for any palliative treatment and were, therefore, excluded from further study.

### Definition of hilar lesion

Hilar strictures were graded according to Bismuth.<sup>30</sup> Type I lesions involved the proximal hepatic duct while sparing the confluence; type II lesions involved the bifurcation but did not extend into the right or left segmental hepatic ducts; type III A and B lesions

involved the confluence and extended into the segmental right and left hepatic ducts respectively; and type IV lesions involved the confluence and extended into both left and right segmental hepatic ducts. Confirmatory histology or cytology was desirable, but the absence of positive cytology did not exclude patients from undergoing treatment in the presence of unequivocal radiological evidence. All patients were reviewed by a specialist HPB radiologist, HPB surgeon and HPB oncologist at the multi-disciplinary meeting (MDT) to confirm the diagnosis of hilar cholangiocarcinoma in the absence of positive cytology.

### Evaluation for treatment

All patients presented with clinical jaundice or deranged liver function that was first evaluated by abdominal ultrasonography, followed by a multi-slice CT scan of the chest, abdomen and pelvis. Patients that were considered for curative surgery were further evaluated by contrast enhanced magnetic resonance imaging (MRI) followed by staging laparoscopy. Loco-regional tumour irresectability was defined according to the criteria proposed by Chamberlain and Blumgart: Bismuth IV tumours; encasement or occlusion of the main portal vein; lobar atrophy with contralateral portal vein involvement; evidence of metastasis to N2 level lymph nodes; and presence of distant metastases.<sup>31</sup>

### Clinical cohorts

All patients within the 5-year study period were prospectively monitored until death (or study end-point – December 2006). Patients with intra-hepatic cholangiocarcinoma (IHCC) were not eligible, whereas patients with a mass-forming hilar cholangiocarcinoma were included in the study. All lesions were stratified according to Bismuth Classification (Table 1) irrespective of the size of the mass lesion at the hilum.

**Table 1** Patient demographics: Bismuth classification – tumour extent. Cohort 1: surgical resection; Cohort 2: stent  $\pm$  chemotherapy; Cohort 3: stent  $\pm$  PDT

	Cohort 1 (n = 10)	Cohort 2 (n = 17)	Cohort 3 (n = 23)
Age (year) (range)	69 (25–78)	65 (44–82)	69 (56–83)
Gender (male/female)	3/7	7/10	13/10
Karnofsky status (%)	90 (65–100)	70 (30–95)	75 (30–100)
Tumour extent <sup>(14)</sup>			
Type I	–	–	–
Type II	2	1	1
Type IIIa	5	4	8
Type IIIb	3	1	2
Type IV	–	11	12
Positive histology	3	9	16
Liver metastases (Stage IV disease)	0	2	3

PDT, photodynamic therapy.

Patients were reviewed in the hepatobiliary oncology MDT meeting to determine suitability for radical surgery or palliative therapy. Only patients with a life expectancy > 6 weeks were considered for systemic chemotherapy or photodynamic therapy (PDT). Four patients with extensive liver metastases (>40% liver volume replaced with tumour) and severe cardiac co-morbidity were considered ineligible for any further treatment and were offered symptom support only.

All eligible patients ( $n = 40$ ) undergoing palliative treatment were offered the choice of (i) standard therapy of stenting  $\pm$  chemotherapy as directed by the multi-disciplinary team or (ii) stent  $\pm$  PDT.

Patients choosing standard therapy were informed that chemotherapy may in some cases prevent disease progression for a limited period. Patients choosing PDT were informed that PDT was an experimental treatment that caused local tumour destruction that may improve liver function and survival, but also caused severe skin photosensitivity for up to 8 weeks which would temporarily compromise quality of life.

Contra-indications to PDT were (i) age <18, (ii) history of porphyria or skin photosensitivity, (iii) life expectancy less than 6 weeks, (iv) and extensive metastatic liver disease (>40%). Four frail elderly patients were excluded on the basis of extensive metastatic liver disease and a predicted survival of less than 6 weeks.

After appropriate out-patient counselling, 17/40 patients selected standard palliative therapy (stent  $\pm$  chemotherapy), and 23/40 patients selected stent  $\pm$  PDT.

#### Cohort 1

Cohort 1 comprised of patients with resectable disease that proceeded to radical surgery which included a hepatic resection and caudate lobectomy as standard procedure. Patients with Type IIIa lesions ( $n = 5$ ) underwent pre-operative portal vein embolization 4–6 weeks prior to extended right hepatectomy (S4–8 plus S1).

#### Cohort 2

Cohort 2 comprised of 17/40 patients with irresectable disease that selected standard therapy as primary palliation. Of these 17 patients, 8 received systemic chemotherapy ( $n = 8$ ). Chemotherapy was not given to nine patients as a result of persistent jaundice despite biliary tree stenting (bilirubin > 50 mmol/l), clinical deterioration or patient decision. The decision to commence, withhold or stop chemotherapy was undertaken by the medical oncologist.

#### Cohort 3

Cohort 3 comprised of 23/40 patients with irresectable disease that selected biliary stent  $\pm$  PDT as primary palliation. All 23 patients underwent PDT as jaundice is not a contra-indication to treatment.

Follow-up for all patients included a clinical out-patient review at 6 and 12 weeks after definitive first treatment, and 3-monthly clinical out-patient review thereafter. Cross-sectional imaging was

repeated at 3, 6 and 12 months, and serial liver function tests [serum bilirubin, alanine aminotransferase (ALT), albumin, alkaline phosphatase (AP), Gamma-glutamyltranspeptidase (gamma-GT)], and the tumour marker CA19.9 were collected at each follow-up visit.

The primary end-point of the study was patient survival. Secondary end-points were PDT toxicity and other treatment related side effects. All data were collected prospectively.

#### Biliary tree decompression at presentation

During their index admission, all patients had a biliary tree stent inserted to relieve jaundice (if possible) and associated symptoms, and multiple brushings obtained for cytology.<sup>32</sup> Patients that presented initially to the Ninewells Hospital hepatobiliary unit underwent biliary tree decompression with insertion of a plastic stent. Seven patients referred from other Institutions had a self-expandable metal stent (SEMS) inserted prior to referral, and these patients had palliative PDT from within the lumen of the SEMS. PDT has been shown to have similar efficacy when delivered from within a metal stent.<sup>29</sup>

#### Curative surgery

Patients with resectable disease underwent partial hepatectomy and caudate lobectomy together with resection of the primary bile duct cancer as standard procedure. Patients with Bismuth Type IIIa lesions required extended hepatic resection and therefore had right portal vein and segment 4 venous embolization (PVE) 4–6 weeks prior to surgery. A CT scan was performed at 4 weeks to confirm future remnant liver (segment 2–3) hypertrophy prior to proceeding with definitive surgery.

#### Chemotherapy

Chemotherapy was directed by a specialist hepatobiliary medical oncologist and patients were treated with ECF (Epirubicin 50 mg/m<sup>2</sup>, Cisplatin 60 mg/m<sup>2</sup>, Fluorouracil 600 mg/m<sup>2</sup>) or Gemcitabine 1 g/m<sup>2</sup>. Chemotherapy was stopped when there was (i) radiological evidence of disease progression or (ii) severe clinical side effects. Biliary tree re-intervention was carried out 'on-demand' if patients presented with cholangitis or jaundice during follow-up. There was no routine planned prophylactic stent change in any patient.

#### Photodynamic therapy

Photofrin® (Axan Pharma Inc., Mount-Saint-Hilaire, Canada) was administered by slow intravenous injection over 5 min at a dosage of 2 mg/kg 48 h before laser activation. All patients received prophylactic antibiotic cover with ciprofloxacin 500 mg, and this was continued twice daily for 2 weeks after PDT. PDT was performed in the radiology suite to provide fluoroscopy imaging and the procedure was carried out under intravenous sedation (midazolam 6–16 mg, pethidine 25–50 mg, Hyoscine Butylbromide 20–80 mg) with cardiac and respiratory monitoring. Oxygen was delivered via a nasal cannula to optimize the effect of the PDT.

Access to the biliary tree was obtained via an ERC duodenoscope or a percutaneous transhepatic catheter (PTC). The optical diffuser fibres delivered 200 mW/cm with an active tip length of 40 mm (CD 405-40 C, BioLitec AG, Jena, Germany). The optical fibre was coupled to a Diomed 630 laser (Diomed, Cambridge, UK) delivering light at a wavelength of 630 nm, which is the optimum wavelength for activation of Photofrin®. The total light dose delivered to the tumour was 180 J/cm. After PDT, the procedure was concluded by immediate insertion of a biliary stent. A single 10F plastic or 10 mm metal stent was placed across the tumour into the left or right side of liver – to preferentially drain the biliary system with most preserved functional liver volume.<sup>32</sup> We consider it important that PDT is tailored towards the liver segments with most functional reserve and this may be delivered via ERC or PTC. Care is taken to avoid contrast injection into un-drained segments, and both stent placement and the PDT procedure are best planned using pre-treatment magnetic resonance cholangiopancreatography (MRCP).

Patients received one PDT treatment only in the study period, and biliary tree re-intervention was carried out 'on-demand' if patients presented with jaundice or cholangitis in the follow-up period. There was no routine planned prophylactic stent change in any patient.

### Statistical Analysis

SPSS® version 16.0 was used for statistical analysis (SPSS Inc., Chicago, IL, USA). Patient survival is presented as mean and median [95% confidence intervals (95% CI)] value for each cohort. Patient survival curves were calculated using Kaplan–Meier methodology and differences in survival between cohorts were tested using the log-rank test. A *P*-value <0.05 was considered to be statistically significant.

## Results

### Patient cohorts

During the study period, 54 patients were referred to the Unit with a diagnosis of hilar cholangiocarcinoma (Table 1). Four patients with severe co-morbidity and extensive metastatic disease (>40%) were not fit for any type of treatment and therefore excluded from any further analysis. The 50 patients suitable for active treatment are the subject of this prospective clinical cohort study.

Ten patients (10/50) had resectable disease and proceeded to undergo radical surgery (Cohort 1). The remaining 40 patients were considered unsuitable for radical resectional surgery and were considered for palliative therapy only. Of these 40 patients, four had resectable disease (Bismuth Type IIIa) but were considered unsuitable for extended hepatic resection as a result of severe co-morbidities (ischaemic heart disease and diabetes mellitus in all four). One of these four patients selected standard palliative therapy, and three selected palliative PDT. Ten out of the 40 patients with irresectable disease were referred from other hepatobiliary centres in Scotland, and 7 of these 10 patients had a SEMS *in situ*.

### Cohort 1: curative resection

Ten patients underwent laparotomy and trial dissection and all proceeded to curative resection. Pre-operative biliary drainage was performed routinely, and the future remnant liver was drained in patients undergoing PVE prior to surgery. Five patients required pre-operative PVE prior to extended right hepatectomy plus caudate lobectomy.

One patient developed progressive and irreversible hepatic dysfunction in the post-operative period after extended right hepatectomy and died from multi-organ failure 145 days after liver resection. A second patient required a re-look laparotomy at 5 weeks for a persistent bile leak from a peripheral duct that was oversewn. The median hospital stay after liver resection was 14 days (range 8–145 days).

Positive pre-operative cytology was obtained in 3 out of 10 patients, but histology of the resected specimen confirmed hilar ductal adenocarcinoma in all 10 patients. An R0 curative resection with negative resection margins was achieved in all cases but positive regional lymph node metastases were noted in four cases.

### Cohort 2: standard palliative therapy

Seventeen out of 40 patients with irresectable disease selected biliary stent ± systemic chemotherapy (in preference to PDT) as their primary palliation. Eight of these 17 patients actually received systemic chemotherapy under the direction of a hepatobiliary medical oncologist. These patients received 2 to 12 cycles of chemotherapy with a mean of 4 cycles per patient. One patient demonstrated a radiological response after 3 cycles, 5 patients had stable disease after 3 cycles, and 2 patients demonstrated progressive disease after 3 cycles and chemotherapy was withdrawn. Three out of five patients with stable disease stopped chemotherapy after the fourth cycle because of treatment side effects and/or disease progression. The remaining nine patients did not commence chemotherapy as a result of a deterioration in clinical condition (*n* = 4), persistent jaundice (*n* = 3) or patient decision (*n* = 2).

### Cohort 3: biliary stent + Photofrin PDT

Twenty-three out of 40 patients with irresectable disease selected biliary stent ± photodynamic therapy as their palliative treatment. PDT was delivered as a single treatment, and was delivered at a median of 2.5 months (range 1.5–7 months) after diagnosis. Access to the biliary tree for delivery of PDT was by duodenoscope (ERC) in 19 patients and percutaneous fluoroscopy (PTC) in 4 patients. All patients that received the photosensitiser drug subsequently underwent successful PDT at 48 h. All patients were treated as hospital in-patients (from day 1 – drug injection), and received intravenous saline for 48 h after PDT. The median hospital stay for PDT was 9.8 days (range 4–32 days), with the observation that patients referred from other Scottish centres stayed 2–4 days longer than local patients.

Jaundice resolved in 21 out of 23 patients after PDT, with bilirubin levels dropping to below 40 mmol/l at 4 weeks after PDT.

Positive histology or cytology was obtained in 16 out of 23 patients, and 5 further patients demonstrated disease progression with metastatic disease on serial follow-up imaging. One patient with a Bismuth Type IIIb lesion met all clinical and radiological criteria in the absence of positive cytology, and remains clinically well with no evidence of metastatic disease at 36 months after PDT.

PDT was reasonably well tolerated, with 10 out of 23 patients reporting mild abdominal pain or discomfort for 2–3 days after PDT. This was treated by simple analgesia and close clinical observation and resolved in all cases.

*Early side-effects* ( $\leq 7$  days) were observed in 7 out of 23 PDT patients. Five patients became unwell with clinical signs of septicaemia in the first 24 h after PDT, and required intravenous fluid replacement and antibiotic therapy. These patients recovered within 48 h and were tolerating normal oral fluids and diet by 72 h after PDT.

Two further patients had a significant haematemesis with cardiovascular compromise within 24 h of PDT. Both patients demonstrated a significant haemoglobin drop to less than 8 gm/dl and required a three-unit blood transfusion of red cell concentrate. Upper GI endoscopy was normal in both patients and it is postulated that these two patients had haemobilia secondary to the biliary tree instrumentation, balloon dilatation and PDT of the hilar lesion. The bleeding was thought to be secondary to direct instrumentation-related trauma, rather than tumour invasion of the portal vessels at the hilum.

*Late side-effects* ( $> 7$  days) were noted in 4 out of 23 patients. Despite extensive counselling by staff about the risk of Photofrin® photosensitivity, four patients inadvertently exposed themselves to direct sunlight and developed minor skin irritation as a consequence. However, this amounted to minor inflammation that was alleviated by anti-histamine emollient cream (Table 2).

After PDT, most patients were re-admitted to their local hospital or the study centre hospital on at least one occasion (mean 1.69; median 1; range 0–6). The reasons for re-admission were cholangitis, progression of jaundice or derangement of liver function, and/or suspected stent occlusion. After re-admission, patients underwent further cross-sectional imaging to document

disease progression, clarify symptom aetiology and plan a strategy for further biliary tract intervention.

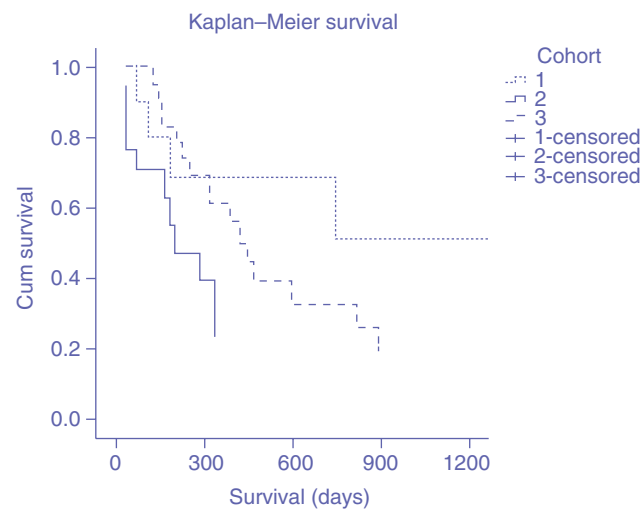
## Survival

At the predetermined end-point (31 December 2006) of this observational study, 4/10 patients in cohort 1, 16/17 patients in cohort 2 and 18/23 patients in cohort 3 had died of progressive disease. The median follow-up for the 40 patients was 25.1 months (range 3–46 months).

The 1-year survival rate was 80% in cohort 1, 12% in cohort 2 and 75% in cohort 3. In cohort 1, the mean (95% CI) survival was 1278 (632, 1923) days and the median survival has not yet been reached. In cohort 2, the mean (95% CI) and median (95% CI) survival was 173 (120, 226) days and 169 (120, 217) days, respectively, which is similar to survivals reported by others for Bismuth Type III-IV hilar cholangiocarcinoma (3–13).

The mean (95% CI) and median (95% CI) survival in cohort 3 was 512 (366, 658) and 425 (260, 589) days, respectively. The median survival observed in cohort 3 is substantially longer than that observed in cohort 2, and this difference in survival is highly significant (log rank  $P < 0.0001$ ).

The Kaplan–Meier survival curves for each patient cohort are illustrated in Fig. 1, and the survival curves for each cohort are



**Table 2** PDT-related adverse events

	Stent + PDT n = 23
Abdominal pain	10
Early side effects (<7 days)	7
Biliary sepsis <sup>a</sup>	5
Haematemesis <sup>a</sup>	2
Late side effects (>7 days)	4
Skin Photosensitivity <sup>b</sup>	4

PDT, photodynamic therapy.

<sup>a</sup>Probably related to procedure related instrumentation.

<sup>b</sup>Related to Photofrin® administration.

**Figure 1** Overall survival – hilar cholangiocarcinoma. Cohort 1: curative surgery; Cohort 2: stent ± chemotherapy; Cohort 3: stent ± photodynamic therapy (PDT). Cohort 1 – mean [95% confidence interval (CI)] survival 1278 (632, 1923) days, median survival not reached. Cohort 2 – mean (95% CI) survival 173 (120, 226) days and median (95% CI) survival 169 (120, 217) days. Cohort 3 – mean (95% CI) survival 512 (366, 658) days and median (95% CI) survival 425 (260, 589) days



truncated when the number at risk are less than 30% of the initial cohort size.

## Discussion

Hilar cholangiocarcinoma is the most common primary cancer of the biliary tract in the United Kingdom with approximately 650 new cases per annum. Whilst curative resection is possible in 20%, most patients require effective palliation. The median predicted survival in those with irresectable disease is approximately 4–6 months.<sup>11–14,34,35</sup> Hilar bile duct cancers spread along the biliary tree to cause progressive bile duct obstruction, hepatic dysfunction and potentially fatal biliary sepsis. Therefore a targeted therapy that is able to control cancer growth at a local level has the theoretical benefit that it may improve drainage of the extra- and intra-hepatic biliary tree, maintain hepatic function and secondarily reduce the risk of serious (potentially fatal) biliary tract infection.

PDT is a non-thermal palliative therapy that causes localized and targeted tissue destruction, induces a systemic T-cell mediated immune response and can be delivered to remote body sites via flexible optical fibres. Therefore PDT has characteristics that are well suited for the palliation of hilar bile duct cancer, and may provide a clinical benefit to patients that have an otherwise extremely bleak outlook.

Several studies report PDT as an effective palliative option, but this modality is not widely available and is not yet considered a standard therapy for patients with hilar bile duct cancer in the United Kingdom. Therefore, this prospective clinical cohort study has compared the current standard palliative therapy of bile duct stent  $\pm$  chemotherapy with the novel combination of bile duct stent  $\pm$  PDT for palliation of patients with irresectable hilar cholangiocarcinoma. All patients were followed up prospectively to provide insight into the impact that these palliative treatment modalities have on this disease. In this study, it was our experience that PDT is associated with an increased survival in patients with irresectable disease.

Previous studies have established that after surgical biliary bypass (drainage) or biliary stenting the median survival is approximately 4–10 months.<sup>7,33,35,36–39</sup> In the present study, the median survival observed with standard treatments (i.e. cohort 2) was 6 months, which is similar to that predicted and reported in other studies.<sup>7,33,35,36–39</sup> To date, trials with systemic chemotherapy have demonstrated radiological responses of 20–40%,<sup>40–42</sup> but limited clinical efficacy in terms of survival gains.<sup>43,44</sup>

In contrast, several phase II studies<sup>25,27,28,45</sup> and a randomized controlled trial<sup>29</sup> have demonstrated a significant survival advantage with PDT, with median survivals ranging from 330–493 days after diagnosis and a 1-year survival of 45–75%.<sup>25,26</sup> In this study, the actual 1-year survival after PDT (cohort 3) was 75%, and the median survival was 425 days. This survival is similar to that reported by Ortnier *et al.*,<sup>29</sup> and substantially longer than that normally predicted for this patient population,<sup>7,33,35,36–39</sup> and signifi-

cantly longer than that observed with standard palliative treatment (stent  $\pm$  chemotherapy) ( $P = 0.0001$  Log rank test).

When one considers the palliative options available for patients with hilar cholangiocarcinoma, PDT offers a single minimally invasive treatment that has a low complication rate, and is well tolerated by patients. In our experience, the side effects of PDT were predictable and relatively easy to treat. When using Photofrin® for biliary PDT, phototoxicity is an inevitable side effect that lasts for 6 to 8 weeks after drug administration. However, patients regarded the avoidance of direct sunlight and intense light as a minor inconvenience.

It was observed that segmental drainage and biliary tract decompression was successful in 21 out of 23 patients undergoing PDT with a 50% reduction in serum bilirubin at 1 month after PDT. An advantage of PDT in hilar cholangiocarcinoma is that it may be delivered to jaundiced patients (unlike chemotherapy) to cause targeted destruction of the intra-luminal tumour at the biliary confluence. This may improve segmental liver drainage and this is supported by recent studies that report a reduction in cholestasis with bile duct PDT.<sup>25–29,46</sup>

Difficulties in obtaining histopathological confirmation of the diagnosis in patients with hilar cholangiocarcinoma are well recognized. This is related to the difficulty in acquisition of adequate cytology and histology,<sup>47</sup> with sensitivities of <50% and <63% reported as either single or combined diagnostic modalities, respectively.<sup>48</sup> We recognize that in this study positive cytology could not be obtained in all patients prior to treatment. However, this reflects this recognized difficulty with hilar cholangiocarcinoma, and all patients within this study had multiple biliary brushings for cytology and confirmed malignancy in 16 out of 23 patients undergoing PDT. Five further PDT patients demonstrated unequivocal evidence of cancer progression on serial cross-sectional imaging, and 18/23 PDT patients have died of cancer progression during the study follow-up period. To date, new techniques such as *in situ* hybridization and fluorescence *in situ* hybridization (FISH) analysis have been unable to improve the diagnostic accuracy beyond that obtained using biliary brushings and cytology.<sup>49,50</sup>

Modern surgical strategies for hilar cholangiocarcinoma require the resection of substantial volumes of functional liver parenchyma to ensure clear resection margins which clearly increases the surgical risk and in-hospital mortality (0–18%).<sup>34,36–38,51–55</sup> However, this radical approach to curative resection can achieve 5-year survival rates of 20–40%, especially in the absence of regional lymph node metastases.<sup>34,36,37,51,53–56</sup> Witzigmann *et al.* recently reported their experience of 156 patients with hilar cholangiocarcinoma and demonstrated that an R0 curative resection remains the optimal treatment. However, in their experience patients with irresectable disease treated with PDT had a survival similar to that of patients that underwent an incomplete R1 or R2 surgical resection<sup>56</sup> and this observation further supports PDT as a beneficial palliative therapy in hilar cholangiocarcinoma.

Historically the prognosis for patients with irresectable hilar cholangiocarcinoma has been poor. However, this single centre prospective clinical cohort study has demonstrated that radical surgery offers the possibility of cure for a small proportion of patients, and also that palliative PDT is associated with an improvement in patient survival. While the outcomes associated with PDT for irresectable hilar cholangiocarcinoma in this phase 2 clinical observational study are encouraging, we await with interest the survival data from the Photostent-02 multi-centre randomized controlled trial that is due to report in 2012.

#### Conflicts of interest

None declared.

#### References

- Altemeier WA, Gall EA, Zininger MM, Hoxworth PI (1957) Sclerosing carcinoma of the major intrahepatic bile ducts. *AMA Arch Surg* 75:450–460; discussion 460–461.
- Klatskin G. (1965) Adenocarcinoma of the hepatic duct at its bifurcation within the porta hepatis. An unusual tumor with distinctive clinical and pathological features. *Am J Med* 38:241–256.
- Carriaga MT, Henson DE (1995) Liver, gallbladder, extrahepatic bile ducts, and pancreas. *Cancer* 75:171–190.
- Chamberlain RS, Blumgart LH (2000) Hilar cholangiocarcinoma: a review and commentary. *Ann Surg Oncol* 7:55–66.
- Thuluvath PJ, Rai R, Venbrux AC, Yeo CJ (1997) Cholangiocarcinoma: a review. *Gastroenterologist* 5:306–315.
- Pitt HA, Dooley WC, Yeo CJ, Cameron JL (1995) Malignancies of the biliary tree. *Curr Probl Surg* 32:1–90.
- Farley DR, Weaver AL, Nagorney DM (1995) 'Natural history' of unresected cholangiocarcinoma: patient outcome after noncurative intervention. *Mayo Clin Proc* 70:425–429.
- Gerhards MF, den Hartog D, Rauws EA, van Gulik TM, Gonzalez Gonzalez D, Lameris JS *et al.* (2001) Palliative treatment in patients with unresectable hilar cholangiocarcinoma: results of endoscopic drainage in patients with type III and IV hilar cholangiocarcinoma. *Eur J Surg* 167:274–280.
- Guthrie CM, Banting SW, Garden OJ, Carter DC (1994) Segment III cholangiojejunostomy for palliation of malignant hilar obstruction. *Br J Surg* 81:1639–1641.
- Lai EC, Chu KM, Lo CY, Fan ST, Lo CM, Wong J (1992) Choice of palliation for malignant hilar biliary obstruction. *Am J Surg* 163:208–212.
- Smith AC, Dowsett JF, Russell RC, Hatfield AR, Cotton PB (1994) Randomised trial of endoscopic stenting versus surgical bypass in malignant low bile duct obstruction. *Lancet* 344:1655–1660.
- Davids PH, Groen AK, Rauws EA, Tytgat GN, Huibregtse K (1992) Randomised trial of self-expanding metal stents versus polyethylene stents for distal malignant biliary obstruction. *Lancet* 340:1488–1492.
- Peters RA, Williams SG, Lombard M, Karani J, Westaby D (1997) The management of high-grade hilar strictures by endoscopic insertion of self-expanding metal endoprotheses. *Endoscopy* 29:10–16.
- Prat F, Chapat O, Ducot B, Ponchon T, Pelletier G, Fritsch J *et al.* (1998) A randomized trial of endoscopic drainage methods for inoperable malignant strictures of the common bile duct. *Gastrointest Endosc* 47:1–7.
- Bruha R, Petrtyl J, Kubecova M, Marecek Z, Dufek V, Urbanek P *et al.* (2001) Intraluminal brachytherapy and selfexpandable stents in nonresectable biliary malignancies – the question of long-term palliation. *Hepatogastroenterology* 48:631–637.
- Shinchi H, Takao S, Nishida H, Aikou T (2000) Length and quality of survival following external beam radiotherapy combined with expandable metallic stent for unresectable hilar cholangiocarcinoma. *J Surg Oncol* 75:89–94.
- Miura Y, Endo I, Togo S, Sekido H, Misuta K, Fujii Y *et al.* (2001) Adjuvant therapies using biliary stenting for malignant biliary obstruction. *J Hepatobiliary Pancreat Surg* 8:113–117.
- Bowling TE, Galbraith SM, Hatfield AR, Solano J, Spittle MF (1996) A retrospective comparison of endoscopic stenting alone with stenting and radiotherapy in non-resectable cholangiocarcinoma. *Gut* 39:852–855.
- Pahernik SA, Dellian M, Berr F, Tannapfel A, Wittekind C, Goetz AE (1998) Distribution and pharmacokinetics of Photofrin in human bile duct cancer. *J Photochem Photobiol B* 47:58–62.
- Korbelik M, Parkins CS, Shibuya H, Cecic I, Stratford MR, Chaplin DJ (2000) Nitric oxide production by tumour tissue: impact on the response to photodynamic therapy. *Br J Cancer* 82:1835–1843.
- Hsi RA, Rosenthal DI, Glatstein E (1999) Photodynamic therapy in the treatment of cancer: current state of the art. *Drugs* 57:725–734.
- Luo Y, Kessel D (1997) Initiation of apoptosis versus necrosis by photodynamic therapy with chloroaluminum phthalocyanine. *Photochem Photobiol* 66:479–483.
- Levy JG, Obochi M (1996) New applications in photodynamic therapy. Introduction. *Photochem Photobiol* 64:737–739.
- McCaughan JS Jr, Mertens BF, Cho C, Barabash RD, Payton HW. (1991) Photodynamic therapy to treat tumors of the extrahepatic biliary ducts. A case report. *Arch Surg* 126:111–113.
- Ortner MA, Liebetruht J, Schreiber S, Hanft M, Wruck U, Fusco V *et al.* (1998) Photodynamic therapy of nonresectable cholangiocarcinoma. *Gastroenterology* 114:536–542.
- Berr F, Wiedmann M, Tannapfel A, Halm U, Kohlhaw KR, Schmidt F *et al.* (2000) Photodynamic therapy for advanced bile duct cancer: evidence for improved palliation and extended survival. *Hepatology* 31:291–298.
- Dumoulin FL, Gerhardt T, Fuchs S, Scheurlen C, Neubrand M, Layer G *et al.* (2003) Phase II study of photodynamic therapy and metal stent as palliative treatment for nonresectable hilar cholangiocarcinoma. *Gastrointest Endosc* 57:860–867.
- Rumalla A, Baron TH, Wang KK, Gores GJ, Stadheim LM, de Groen PC. (2001) Endoscopic application of photodynamic therapy for cholangiocarcinoma. *Gastrointest Endosc* 53:500–504.
- Ortner ME, Caca K, Berr F, Liebetruht J, Mansmann U, Huster D *et al.* (2003) Successful photodynamic therapy for nonresectable cholangiocarcinoma: a randomized prospective study. *Gastroenterology* 125:1355–1363.
- Bismuth H, Corlette MB (1975) Intrahepatic cholangioenteric anastomosis in carcinoma of the hilus of the liver. *Surg Gynecol Obstet* 140:170–178.
- Vauthey JN, Blumgart LH (1994) Recent advances in the management of cholangiocarcinomas. *Semin Liver Dis* 14:109–114.
- Chang WH, Kortan P, Haber GB (1998) Outcome in patients with bifurcation tumors who undergo unilateral versus bilateral hepatic duct drainage. *Gastrointest Endosc* 47:354–362.
- Polydorou AA, Cairns SR, Dowsett JF, Hatfield AR, Salmon PR, Cotton PB *et al.* (1991) Palliation of proximal malignant biliary obstruction by endoscopic endoprosthesis insertion. *Gut* 32:685–689.

34. Jarnagin WR, Fong Y, DeMatteo RP, Gonen M, Burke EC, Bodniewicz BJ *et al.* (2001) Staging, resectability, and outcome in 225 patients with hilar cholangiocarcinoma. *Ann Surg* 234:507–517; discussion 517–519.
35. Deviere J, Baize M, de Toef J, Cremer M. (1988) Long-term follow-up of patients with hilar malignant stricture treated by endoscopic internal biliary drainage. *Gastrointest Endosc* 34:95–101.
36. Kawasaki S, Imamura H, Kobayashi A, Noike T, Miwa S, Miyagawa S (2003) Results of surgical resection for patients with hilar bile duct cancer: application of extended hepatectomy after biliary drainage and hemihepatic portal vein embolization. *Ann Surg* 238:84–92.
37. Hemming AW, Reed AI, Fujita S, Foley DP, Howard RJ (2005) Surgical management of hilar cholangiocarcinoma. *Ann Surg* 241:693–699; discussion 699–702.
38. Pichlmayr R, Weimann A, Klempnauer J, Oldhafer KJ, Maschek H, Tusch G *et al.* (1996) Surgical treatment in proximal bile duct cancer. A single-center experience. *Ann Surg* 224:628–638.
39. Liu CL, Lo CM, Lai EC, Fan ST (1998) Endoscopic retrograde cholangiopancreatography and endoscopic endoprosthesis insertion in patients with Klatskin tumors. *Arch Surg* 133:293–296.
40. Taieb J, Mitry E, Boige V, Artru P, Ezenfis J, Lecomte T *et al.* (2002) Optimization of 5-fluorouracil (5-FU)/cisplatin combination chemotherapy with a new schedule of leucovorin, 5-FU and cisplatin (LV5FU2-P regimen) in patients with biliary tract carcinoma. *Ann Oncol* 13:1192–1196.
41. Sanz-Altamira PM, Ferrante K, Jenkins RL, Lewis WD, Huberman MS, Stuart KE. (1998) A phase II trial of 5-fluorouracil, leucovorin, and carboplatin in patients with unresectable biliary tree carcinoma. *Cancer* 82:2321–2325.
42. Ellis PA, Norman A, Hill A, O'Brien ME, Nicolson M, Hickish T *et al.* (1995) Epirubicin, cisplatin and infusional 5-fluorouracil (5-FU) (ECF) in hepatobiliary tumours. *Eur J Cancer* 31A:1594–1598.
43. Patt YZ, Hassan MM, Lozano RD, Waugh KA, Hoque AM, Frome AI *et al.* (2001) Phase II trial of cisplatin, interferon alpha-2b, doxorubicin, and 5-fluorouracil for biliary tract cancer. *Clin Cancer Res* 7:3375–3380.
44. Chen JS, Lin YC, Jan YY, Liao CT (2001) Mitomycin C with weekly 24-h infusion of high-dose 5-fluorouracil and leucovorin in patients with biliary tract and periampullar carcinomas. *Anticancer Drugs* 12:339–343.
45. Wiedmann M, Berr F, Schiefke I, Witzigmann H, Kohlhaw K, Mossner J *et al.* (2004) Photodynamic therapy in patients with non-resectable hilar cholangiocarcinoma: 5-year follow-up of a prospective phase II study. *Gastrointest Endosc* 60:68–75.
46. Pereira SP, Ayaru L, Rogowska A, Mosse A, Hatfield AR, Bown SG (2007) Photodynamic therapy of malignant biliary strictures using meso-tetrahydroxyphenylchlorin. *Eur J Gastroenterol Hepatol* 19:479–485.
47. Henke AC, Jensen CS, Cohen MB (2002) Cytologic diagnosis of adenocarcinoma in biliary and pancreatic duct brushings. *Adv Anat Pathol* 9:301–308.
48. Ponchon T, Gagnon P, Berger F, Labadie M, Liaras A, Chavaillon A *et al.* (1995) Value of endobiliary brush cytology and biopsies for the diagnosis of malignant bile duct stenosis: results of a prospective study. *Gastrointest Endosc* 42:565–572.
49. Baron TH, Harewood GC, Rumalla A, Pochron NL, Stadheim LM, Gores GJ *et al.* (2004) A prospective comparison of digital image analysis and routine cytology for the identification of malignancy in biliary tract strictures. *Clin Gastroenterol Hepatol* 2:214–219.
50. Kipp BR, Stadheim LM, Halling SA, Pochron NL, Harmsen S, Nagorney DM *et al.* (2004) A comparison of routine cytology and fluorescence in situ hybridization for the detection of malignant bile duct strictures. *Am J Gastroenterol* 99:1675–1681.
51. Todoroki T, Kawamoto T, Koike N, Takahashi H, Yoshida S, Kashiwagi H *et al.* (2000) Radical resection of hilar bile duct carcinoma and predictors of survival. *Br J Surg* 87:306–313.
52. Gerhards MF, van Gulik TM, de Wit LT, Obertop H, Gouma DJ. (2000) Evaluation of morbidity and mortality after resection for hilar cholangiocarcinoma – a single center experience. *Surgery* 127:395–404.
53. Kitagawa Y, Nagino M, Kamiya J, Uesaka K, Sano T, Yamamoto H *et al.* (2001) Lymph node metastasis from hilar cholangiocarcinoma: audit of 110 patients who underwent regional and paraaortic node dissection. *Ann Surg* 233:385–392.
54. Kondo S, Hirano S, Ambo Y, Tanaka E, Okushiba S, Morikawa T *et al.* (2004) Forty consecutive resections of hilar cholangiocarcinoma with no postoperative mortality and no positive ductal margins: results of a prospective study. *Ann Surg* 240:95–101.
55. Seyama Y, Kubota K, Sano K, Noie T, Takayama T, Kosuge T *et al.* (2003) Long-term outcome of extended hemihepatectomy for hilar bile duct cancer with no mortality and high survival rate. *Ann Surg* 238:73–83.
56. Witzigmann H, Berr F, Ringel U, Caca K, Uhlmann D, Schoppmeyer K *et al.* (2006) Surgical and palliative management and outcome in 184 patients with hilar cholangiocarcinoma: palliative photodynamic therapy plus stenting is comparable to R/R2 resection. *Ann Surg* 244:230–239.